

ORIGINAL PAPERS

Tuberculosis of Testis: a Rare Disease

Vasilica Minciuna¹, Ovidiu Gabriel Bratu^{2,3}, Octavian Cretu¹

Abstract:

Introduction: Genitourinary system is the most common extrapulmonary site after lymph node and lung involvement of tuberculosis.

Tuberculosis can affect epididymis, testis, prostate, seminal vesicle, vas deferens, scrotal skin, bulbourethral glands and/or penis. Diagnosis is difficult to establish because there are no pathognomonic signs and usually it has symptoms similar to a testicular cancer. If radiologic and laboratory findings are not enough to put the diagnosis, then the orchidectomy followed by histopathologic exam are the best options to be made. **Material and methods:** This article is a case report of a 74 years old man with tuberculous right testis. Clear diagnosis was established after orchidectomy was performed and histopathological evaluation of the testis was made. **Results:** Our patient immediately started antituberculous therapy with good response to it. The patient was assessed at 6 months and 1 year after starting antituberculous therapy. His evolution was good. No other pulmonary and neither extrapulmonary relapses were found.

Keywords: tuberculosis, genitourinary tract, testis, *M. tuberculosis*.

Rezumat

Introducere: Tractul genitourinar reprezintă una dintre cele mai frecvente localizări ale tuberculozei după plămâni și sistemul limfo-ganglionar. Tuberculoza poate afecta testiculul, epididimul, prostata, veziculele seminale, ducturile deferente, pielea scrotului, glandul bulbouretral sau penisul. Diagnosticul acestei afecțiuni este greu de pus întrucât nu există semne patognomonice, iar simptomatologia se confundă foarte ușor cu cea a unui cancer testicular. Dacă explorările radiologice și de laborator nu sunt suficiente în stabilirea diagnosticului, atunci orhidectomia urmată de examinarea histopatologică a piesei rămân metodele certe atât în corecția diagnosticului cât și în stabilirea conduitei terapeutice ulterioare. **Material și metodă:** Articolul de față este o prezentare a unui caz clinic de tuberculoză testiculară dreaptă, operată la un pacient în vârstă de 74 de ani. Diagnosticul de certitudine a fost stabilit după efectuarea orhidectomiei drepte și analiza histopatologică a piesei ablate. **Rezultate:** După stabilirea diagnosticului cert de tuberculoză testiculară dreaptă, operată, pacientul a început terapia antituberculoasă specifică, cu evoluție favorabilă.

Cuvinte cheie: tuberculoză, genitourinar, testicul, *M. tuberculosis*.

INTRODUCTION

Tuberculosis represents one of the most important problems in public health. It is an intensely studied infectious disease, in the past and also in present^{2,3}.

The incidence of tuberculosis is decreasing in most industrialized countries due to the improvement of

prevention and therapeutic means (BCG vaccination, antituberculostatic therapy)³.

Romania is among the first countries in the incidence of pulmonary tuberculosis. Annually, 130 new cases per 100000 inhabitants are reported³.

The Global Tuberculosis Report developed by the *World Health Organisation* highlights the following:

¹ Emergency County Hospital, Slobozia, Romania

² „Carol Davila” Central Military Emergency University Hospital, Bucharest, Romania

³ „Carol Davila” University of Medicine and Pharmacy, Bucharest, Romania

Corresponding author:

Vasilica Minciuna

Sf. Gheorghe Street, no. 35, bl. 1, ap. 4, Popesti Leordeni, Ilfov, Romania.

E-mail: dr.minciunavali@gmail.com

Regarding the localisation of tuberculosis, the respiratory system represented 92.0% of the newly registered tuberculous patients over the year and 96.6% of the readmitted³.

Extrapulmonary tuberculosis has a 8.0% rate of the newly registered patients (from which 13.3% represent osteoarticular tuberculosis, 30.1% represent lymph node tuberculosis, 6.3% represents urogenital tuberculosis and 47.3% have other localisation) and 3.4% of the readmitted patients³.

An important phenomenon that has been studied is resistance to antituberculous drugs³.

Drug resistance was reported in 105 countries in 2015^{2,3}.

In Romania, the mortality rate for tuberculosis is 6.4% for every 100000 inhabitants, above the European average of 5.3%; our country ranks the 6th place in Europe³.

Genitourinary tract represents one of the most common extrapulmonary location, after the lung, lymphatic system and osteoarticular system^{2,3,4}.

Tuberculosis can affect epididymis, testis, prostate, seminal vesicle, vas deferens, scrotal content, and penis fully.

Incidence of genitourinary tuberculosis in men is generally low, due to the difficulty of diagnosing².

In postmortem clinical trials, the literature suggests that 70% of men who died of pulmonary tuberculosis also had prostatic tuberculosis undiagnosed during life².

If diagnose is not established in time, genitourinary tuberculosis may also cause infertility⁹.

Genitourinary tuberculosis has no specific symptoms: painful scrotal mass can be initially confused with orchiepididymitis².

The clinical examination finds a rough adherent mass which is painful on palpation, with a favorable response to antibiotic and anti-inflammatory treatment; symptoms disappear after 2-4 weeks.

The diagnosis of testicular tuberculosis is difficult to establish because there are no pathognomonic signs and symptomatology is easily confused with that of testicular cancer.

It should also be considered that genitourinary tuberculosis is a rare complication of BCG (Calmette-Guerin Bacillus) therapy for urothelial and bladder cancers².

Urogenital tuberculosis is usually associated with renal tuberculosis in 60 to 65% of the cases and with pulmonary tuberculosis in 34% of the cases².

Dissemination of tuberculosis infection in the testis can lead to secondary infection of the epididymis. In

the testis is formed a dense, caseous mass that can overinfect after a period of silent evolution. Overinfection can lead to its external fistulizing⁵.

The anatomopathological examination occupies the first place in establishing the etiological diagnosis of testicular tuberculosis^{4,5}.

The presence of epithelioid cell granulomatous tissue, giant Langhans cells with caseous and necrotic areas, corroborated with clinical suspicion, are sufficient to establish the diagnosis, independently of cell culture results^{4,5}.

Other screening methods:

- In laboratory examination, sterile pyuria can lead to epididymal tuberculosis¹.
- Mycobacterium tuberculosis can be identified in urine in 64% of cases of genitourinary tuberculosis by specific media detection¹.
- Leukospermia can be an early symptom of infertility caused by tuberculosis. Prostatic fluid should be investigated by microscopic examination and by cultures on *Mycobacterium tuberculosis* specific media^{1,10}.
- With high sensitivity and specificity: chain polymerization technique that analyzes genetically bacillus from tissue biopsy. A negative result does not invalidate tuberculous infection¹⁰.
- Computer tomography (CT), testicular ultrasound does not show characteristic images (usually cavitory or cystic lesions) and it is often confused with a testicular tumor^{1,10}.
- Transrectal high resolution ultrasonography has become a non-invasive technique applicable to men with low fertility (oligospermia and azospermia). This method can show up abnormalities of the seminal vesicle, ejaculatory duct, prostate appearance, dilations, fibrosis, atrophy, calcifications of the epididymis, seminal vesicle or prostate^{4,5}.
- Intravenous pyelography is considered to be a routine method in tuberculous orchiepididymitis⁵.
- Cutaneous PPD testing is unspecific, especially in Romania, where the prevalence of tuberculosis is increased.

Other investigations, such as renal angiography or renal nuclear scans are associated with suspected coexistence of renal tuberculosis¹.

Differential diagnosis of testicular TB can be done mainly with:

- testicular cancer, but histopathological examination establishes etiology.

- Inflammatory-infectious processes, such as orchiepididymitis
- Benign testicular tumors
- prostatic invasion of adjacent tumor organs
- Genitourinary syphilis

Elective treatment remains antituberculosis therapy. If the lesions caused by testicular tuberculosis are fibrous, nodular, tough, then orchidectomy is considered^{4,5,6}.

CASE REPORT

We present a case of 74 years old patient, retired, who lives in the countryside, that arrives in the ambulatory of The County Emergency Hospital Slobozia, with pain and tumefaction of the right testicle, starting 48 hours ago, with progressive worsening. The patient took acetaminophen on his own initiative with no response.

The urological clinical examination shows by inspection and palpation, swollen, rough and painful right testis.

The ultrasound scan identifies a pseudotumor mass located in the right testicle, with no other particularities.

In the personal pathological history, the patient has: chronic ischemic heart disease, arterial hypertension with specific treatment, chronic smoker bronchitis therapeutically neglected but with stationary evolution.

In the context of his advanced age, comorbidities, clinical and ultrasound examination, we decided to have the patient hospitalized for further exploration.

During hospitalization, the following analysis are done:

- biological samples show leukocytosis (11000/mmc), normal hemoglobin and normal kidney function tests.
- We mention that in hospital laboratory we could not have carried out beta-HCG, alpha-fetoprotein

and HDL, that would have better supported the diagnosis of testicular cancer.

- Urinalysis and uroculture are within normal limits
- Cardiopulmonary x-ray shows: enlarged heart, accentuated pulmonary vascular pattern, with no other pathological elements.
- Interdisciplinary cardiac and pulmonary consults – stable and stationary at the time of the examination

Following clinical and urological paraclinical examination (within the limits of hospital endowment), it is established the diagnosis of right testicular tumor.

Drug therapy with intravenous antibiotics (third generation cephalosporin), antialgic, non-steroidal anti-inflammatory, gastric protection) is initiated; evolution is slightly favorable (reduced swelling, amelioration of testicular pain).

The patient is informed about the diagnosis, medical and surgical therapy, surgical and postsurgical risks.

After obtaining the informed consent, it is decided and put into practice with rachianesthesia: right orchidectomy by inguinal approach.

Intraoperative, an infiltrated testicle with adhesions and nodules is discovered. The extirpated piece is sent to the Anatomopathology department for analysis.

The postoperative progression was favorable.

The patient is discharged 5 days postoperative with the surgical wound undergoing healing.

The patient returns after 2 days to have the inguinal stitches removed and after 3 weeks to obtain the result of the histopathological examination.

After 3 weeks, the result of the histopathological examination presents a suggestive description of testicular tuberculosis. The diagnosis of testicular cancer has been invalidated.

The patient is sent to the Department of Pneumology for further exploration and specific treatment.

Sputum examination, bronchoscopy lavage, pulmonary x-ray infirm tuberculosis or sequelae of pulmonary tuberculosis.

The pneumologist initiates antituberculosis therapy to suppress bacillary infection and prevent the recurrence of other extrapulmonary outbreaks.

Six months after initiating antituberculosis therapy, the patient as a good medical condition, cardiopulmonary compensated.

From the urologic point of view, the patient is clinically asymptomatic and the ultrasound does not show any pathological changes.

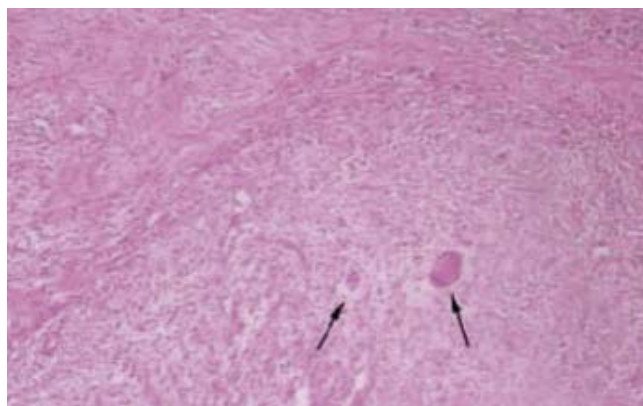


Figure 1. Langhans giant cells – (col H&E,x40).

DISCUSSIONS

Although it is a rare disease, in the differential diagnosis of scrotal masses, tuberculosis should be taken into account. This increases the possibility of early diagnosis and treatment.

In this case, the right testicular pseudotumoral formation was investigated and surgically treated as a testicular cancer, as there were no other clinical and paraclinical indications that would lead to the diagnosis of testicular TB.

It should also be mentioned that in the clinic where the patient was hospitalized, there could not be taken tests such as alpha-fetoprotein, beta-hcg and HDL, that would have better support the diagnosis of testicular cancer. These investigations are not yet carried out in our medical laboratory and the patient did not have financial possibilities to have them carried out in a close private center.

As peculiarities of the case, we mention:

- lack of association of pulmonary or other extrapulmonary tuberculosis;

- favorable progression under surgical treatment followed by antituberculous chemotherapy, despite advanced age and preexisting bronchial and cardiac conditions;
- certain diagnosis was established by histopathological examination of the surgical piece.

CONCLUSIONS

The incidence of genitourinary tuberculosis is not very high, but it remains a major extrapulmonary location, after osteoarticular tuberculosis and lymph node tuberculosis.

Diagnosis is difficult to establish because of no specific symptomatology, that is often confused with orchiepididymitis or testicular cancer.

Literature states that the failure to repeated antibiotic therapy should direct the practitioner to the diagnosis of genitourinary tuberculosis.

References

1. Engin G, Acuna B, Acuna G, Tunaci M. (2000) Imaging of extrapulmonary tuberculosis. *Radiographics* 20: 471-488.
2. Lenk S, Schroeder J (2001) Genitourinary tuberculosis. *Curr Opin Urol* 11: 93-98.
3. Lungu E., Alexandru E.C. Analiza de situație TBC 2016. Institutul Național de Sănătate publică. 2016 1456: 1-31.
4. Kulchavenya E. Urogenital tuberculosis: definition and classification. *Ther Adv Infect Dis*. 2014 Oct. 2 (5-6):117-22.
5. Muttarak M, Peh WC, Lojanapiwat B, Chaiwun B Tuberculous epididymitis and epididymo-orchitis: sonographic appearances. *AJR Am J Roentgenol* 2011 .176: 1459-1466.
6. Perkins GW. Double consecutive castration for primary tuberculosis of testicles. *Ann Surg*. 1889;10(3):169-70.
7. Rajpal S, Dhingra V, Malik M, Kumar R (2002) Tuberculous epididymo-orchitis treated with intermittent therapy: A case report. *Indian J Allergy Asthma Immunol* 16:51-54.
8. Senzaki H, Watanabe H, Ishiguro Y. A case of very rare tuberculosis of the testis. *Nihon Hinyokika Gakkai Zasshi*. 2001;92(4):534-7
9. Sole-Balcells F, Jimenez-Cruz F, de Cabezon JS, Rosello AS (1977) Tuberculosis and infertility in men. *Eur Urol* 3: 129-131.
10. Wang LJ, Wong YC, Chen CJ, Lim KE (1997) CT features of genitourinary tuberculosis. *J Comput Assist Tomogr* 21: 254-258.