

ORIGINAL PAPERS

# Optimizing the Surgical Approach in Hypertrophic Pyloric Stenosis – the Utility of Different Types of Surgical Incisions

Costin Datu<sup>1</sup>, Olivia Stanciu<sup>1</sup>, Mircea Andriescu<sup>1</sup>, Catalin Chiriac-Babei<sup>1</sup>

## Abstract

**Objective:** Most of the alterations to the surgical management of hypertrophic pyloric stenosis (HPS) were related to the approach used in order to minimize the invasiveness of the surgical act. The objective of this study is to describe our experience in treating HPS, with emphasis on types of surgical approaches. **Methods:** This is a retrospective study which analyzes the patients with HPS treated in the surgical department of the Clinical Emergency Hospital for Children "Grigore Alexandrescu", from 2012 to 2016, noting the incision types and outcome variables such as time to first feed and duration of admission. **Results and discussion:** The cohort included 60 patients, with the following incision choices: supraumbilical, xyphoumbilical, semicircumbilical and transverse. The xyphoumbilical and supraumbilical incisions had the shortest time to first feed (1.5 and 1.6 days respectively) and also the shortest duration of admission (7.6 days each). The circumbilical and supraumbilical access points are currently gaining popularity. Although related to a slightly increased time to recovery, they are preferred for better cosmesis and better exposure obtained by using smaller incisions. **Conclusion:** Regarding the open surgery for HPS, the improvement was focused on limiting the invasiveness of the operation by using inconspicuous access routes like periumbilical incisions.

**Keywords:** pylorus, stenosis, surgical incisions, circumbilical approach

## Rezumat

**Obiectiv:** Majoritatea modificărilor managementului chirurgical al stenozei hipertrofice de pilor (SHP) au fost legate de abordul folosit, în scopul unui act chirurgical minim invaziv. Obiectivul studiului este de a descrie experiența noastră în tratamentul SHP, subliniind tipurile de abord chirurgical. **Metode:** Studiul analizează retrospectiv pacienții cu SHP operați în Spitalul Clinic de Urgență pentru Copii „Grigore Alexandrescu” între 2012-2016, notând tipurile de incizie folosite și variabilele de răspuns precum timpul până la reluarea alimentației orale și durata internării. **Rezultate și discuții:** Eșantionul include 60 de pacienți, cu următoarele incizii folosite: supraombilicală, xifoombilicală, semicircumombilicală și transversală. Cea xifoombilicală și cea supraombilicală au prezentat cea mai precoce reluare a alimentației orale (1,5, respectiv 1,6 zile) și, de asemenea, cea mai scurtă durată de internare (fiecare 7,6 zile). S-a observat o tendință de creștere în utilizarea inciziilor circumombilicală și supraombilicală. Deși cu recuperare ușor mai lentă, au fost preferate datorită unui aspect estetic superior și datorită unei expuneri intraoperatorii relativ mai bune la dimensiunea inciziei. **Concluzii:** În ceea ce privește tratamentul chirurgical deschis pentru SHP, îmbunătățirile s-au concentrat pe limitarea invazivității prin folosirea unor căi de acces puțin evidente precum inciziile periombilicale.

**Cuvinte cheie:** pilor, stenoză, incizii chirurgicale, abord periombilical

<sup>1</sup> Department of Pediatric Surgery, Clinical Emergency Hospital for Children "Grigore Alexandrescu", Bucharest, Romania

### Corresponding author:

Catalin Chiriac-Babei

Department of Pediatric Surgery, Clinical Emergency Hospital for Children "Grigore Alexandrescu", Bucharest, Romania.

E-mail: cbcatalin@yahoo.com

## INTRODUCTION

Hypertrophic pyloric stenosis (HPS) is the most common surgical indication for children during the first six months of life<sup>1</sup>. In infants with HPS, the pyloric canal is elongated, its muscular walls severely thickened with an edematous mucosa. As a result, the pyloric relaxation is markedly restricted, causing upper digestive obstruction<sup>2</sup>.

HPS is manifested between the first week and the first 3 months of life, with a predilection for Caucasian males<sup>3</sup>. Clinical presentation is marked by projectile non-bilious vomiting and failure to thrive. In extreme cases, dehydration and electrolyte imbalance are severe and death may ensue.

The diagnosis is made in some cases by physical examination, by palpating the “pyloric oliva” – the hypertrophied pyloric canal. This is a very specific sign for HPS, but it lacks sensitivity<sup>4</sup>. The confirmation is obtained by imagistic explorations, especially by ultrasound examination, in most pediatric centers, which is considered the “gold standard” by many investigators<sup>4</sup>.

Although several studies reported good outcomes with medical therapy<sup>5</sup>, surgery is the mainstay for treatment of HPS. Surgical pyloromyotomy is the standard procedure, and had little variations since its introduction by Ramstedt in 1912. It consists of a longitudinal incision of the pyloric muscle, allowing the mucosa to protrude through the incision, without suturing it. The technique is curative and has a very low morbidity<sup>6</sup>.

Most of the alterations to the original operation were mostly related to the approach used with the objective to minimize the invasiveness of the surgical act. Therefore, several types of incisions were introduced, in

an attempt to reduce the morbidity, increase recovery and for better cosmesis. Alternatively, laparoscopic and robotic procedures were reported<sup>7,8</sup>.

This paper describes the experience with different types of incisions used in the Clinical Emergency Hospital for Children “Grigore Alexandrescu”, emphasizing the different outcomes in terms of morbidity and recovery.

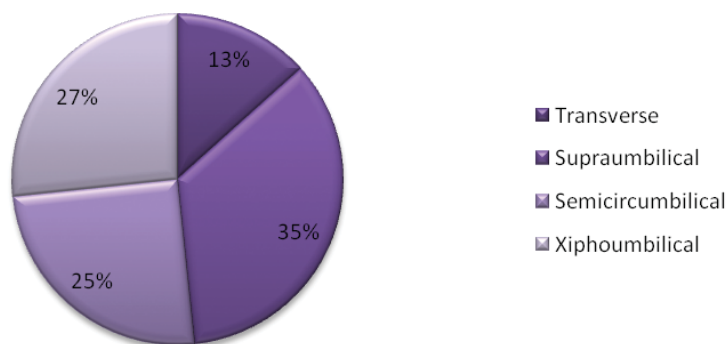
## MATERIALS AND METHODS

The study consists of a retrospective analysis of the patients with HPS operated in the surgical department of the Clinical Emergency Hospital for Children “Grigore Alexandrescu” in Bucharest over a five year time period between 2012 and 2016. After collecting the demographic data, we classified the patients by incision type and recorded outcome variables such as time of first oral feed and time of discharge. The information was stored and analyzed using Microsoft Excel 2007. Using the data analysis tool pack, the correlation and regression tests were performed and a p value of <0.05 was considered significant. Contingency tables were used and the chi squared test was performed to assess the goodness of fit for some of the compared variables, with the Cramer’s V test being used to test the strength of the results obtained from the chi square test.

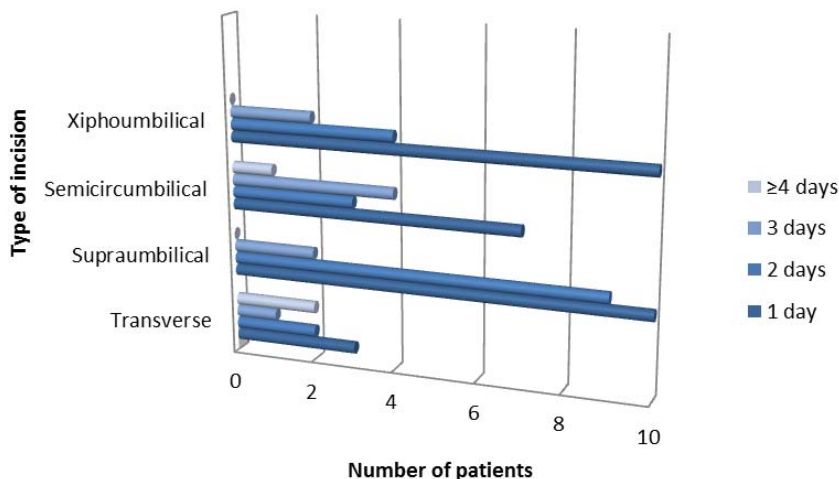
## RESULTS

The cohort consists of 60 patients, mostly males (92%), with a median age at presentation of 31 days. All operations were performed by an open approach with several incision choices. The most common incision type

### Percentage of patients based on surgical incision



**Figure 1.** Percentage of patients based on incision.



**Figure 2.** Onset of oral feeding in relation to the type of incision used.

was the supraumbilical incision (21 patients) (Figure 1), followed by the xyphoumbilical (16 patients), semicircumbilical (15 patients) and abdominal transverse incision (8 patients) (Figure 1).

The average duration from the time of surgery until oral feeding was 1.85 days. The shortest duration was 1 day, which was seen in half of the patients, and the longest duration was 7 days (in 2 patients) (Figure 2).

The shortest duration from the time of surgery till the onset of oral feeding was in the subgroups with xyphoumbilical and supraumbilical incisions. Oral fe-

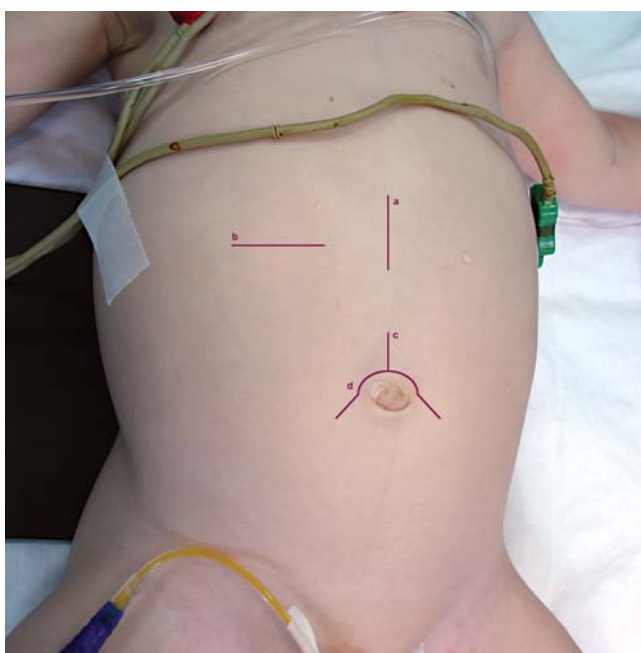
eding was resumed after 2 days or less in 87.5% of the patients with xyphoumbilical incision, 90% of those with supraumbilical incision, and only 62.5% and 66.7% respectively, in case of transverse and semicircumbilical incisions. The regression analysis produced a p value of 0.10 and the chi square test produced a p value of 0.17. The average duration till onset of oral feeding for the different types of surgical incision was as follows: 2.6 days for transverse incision, 1.6 days for supraumbilical incision, 2.1 days for semicircumbilical incision, and 1.5 days for xyphoumbilical incision.

The median length of admission in this group was 7 days, with the shortest being 3 days (in 2 patients) and the longest being 30 days. The average duration of admission in relation to the type of surgical incision was 9.4 days for transverse incision, 7.6 days for supraumbilical incision, 8.5 days for semicircumbilical incision and 7.6 days for xyphoumbilical incision.

## DISCUSSION

The best incision is the one which facilitates optimal exposure with minimal trauma, allows extension, provides the greatest tensile strength and maximizes the patient’s comfort and as well as the cosmetic result<sup>9</sup>.

For the surgical treatment of HPS, different types of incisions may be used. The “traditional” midline xyphoumbilical incision (Figure 3a) was used more commonly in the past. It was replaced by the transverse type of incision (Figure 3b) which had the advantages of creating better exposure by being more adapted for the ellipsoidal shape of the infant’s abdomen<sup>9</sup>. It can also be extended more easily and there is virtually no need for self-retaining retractors. On the other hand, by cre-



**Figure 3.** Types of incision used for pyloromyotomy a. midline; b. transverse; c. supraumbilical; d. circumbilical.

ating the incision along the skin tension lines, a better cosmesis is achieved<sup>9</sup>.

The supraumbilical (Figure 3c) and circumbilical incisions (Figure 3d), as introduced by Tan and Bianchi<sup>10</sup> are minimally invasive approaches which compared with the transverse incision, provide greater operative flexibility, and result in superior cosmetic outcome, with virtually non-observable scar<sup>11</sup>.

The midline xyphumbilical incision used to be the preferred type of incision due to the quicker recovery of the patients, but, currently, the circumbilical and supraumbilical access points are gaining popularity. The reasons for abandoning the midline xyphumbilical

incision are poor cosmetic results and limited exposure in spite of the size of the incision.

## CONCLUSION

HPS is a common condition in otherwise healthy infants. Its treatment has become straightforward with very high success rates. Therefore, the research in pediatric surgery is focused on limiting the invasiveness of this procedure by using inconspicuous access routes like periumbilical incisions, or like some advocate, using high end technology like laparoscopic or robotic interventions.

## References

1. Oue T, Puri P. Smooth Muscle Cell Hypertrophy versus Hyperplasia in Infantile Hypertrophic pyloric Stenosis. *Pediatr Res* [Internet] 1999;45(6):853–7.
2. Hernanz-Schulman M. Infantile Hypertrophic Pyloric Stenosis. *Radiology* 2003;227(2):319–31.
3. Fischer JE, Bland KI. *Mastery of surgery* [Internet]. Wolters Kluwer Health/Lippincott Williams & Wilkins; 2007.
4. Glatstein M, Carbell G, Sirisha Kusuma Boddu SK, Bernardini A, Scolnik D. The Changing Clinical Presentation of Hypertrophic Pyloric Stenosis: The Experience of a Large, Tertiary Care Pediatric Hospital. *Clin Pediatr (Phila)* [Internet] 2011;50(3):192–5.
5. Kawahara H, Takama Y, Yoshida H, Nakai H, Okuyama H, Kubota A, et al. Medical treatment of infantile hypertrophic pyloric stenosis: should we always slice the “olive”? *J Pediatr Surg* [Internet] 2005;40(12):1848–51.
6. Hay WW. *Current pediatric diagnosis and treatment* [Internet]. Lange Medical Books/McGraw-Hill, Medical Pub. Division; 2003.
7. Handu AT, Jadhav V, Deepak J, Aihole JS, Gowrishankar, Narendrababu M, et al. Laparoscopic pyloromyotomy: Lessons learnt in our first 101 cases. *J Indian Assoc Pediatr Surg* 2014; 19(4):213–7.
8. Anwar MO, Omran Y AI, Al-Hindi S. Laparoscopic Pyloromyotomy: A Modified Simple Technique. *J neonatal Surg* [Internet] 2016;5(1):3.
9. Gauderer MW. A rationale for routine use of transverse abdominal incisions in infants and children. *J Pediatr Surg* [Internet] 1981;16(4 Suppl 1):583–6.
10. Tan KC, Bianchi A. Circumumbilical incision for pyloromyotomy. *Br J Surg* [Internet] 1986;73(5):399.
11. Horwitz JR, Lally KP. Supraumbilical skin-fold incision for pyloromyotomy. *Am J Surg* [Internet] 1996;171(4):439–40.