

## ORIGINAL PAPERS

# The Value of Computed Tomography in Establishing the Proper Surgical Treatment of a Complex Proximal Humerus Fracture

Razvan Turcu<sup>1,2</sup>, Marius Moga<sup>1,2</sup>, Mircea Ifrim<sup>3</sup>

## Abstract

In case of comminuted fractures or displaced humeral tuberosities fractures, cases where radiographs are not edifying, computerized tomography is recommended. Combination fractures with 3 and 4 fragments affect the glenohumeral joint surface and pose a significant risk of damage to the proximal humerus vasculature. Aseptic osteonecrosis of the humeral head is more common following comminuted fractures with 4 fragments. Following conventional radiographs, it is difficult to classify a fracture in a patient with obvious symptoms. Compared to conventional radiographs, computerized tomography with 2D or 3D reconstructions clearly shows the fracture and the degree of displacement of fragments without overlapping. In addition, information about fragment shifting, impact, coincidence, and subluxation can be highlighted. In this study we want to evaluate and compare the results and benefits of computerized tomography: correcting the errors of an initial diagnosis; precise diagnosis, a high accuracy classification of proximal third humeral fractures, being of real use in preoperative planning; The need for direct spatial visualization of the realignment of fracture fragments, which reduces the intra-operative decision-making time for the subsequent evolution of the case. The success of the treatment depends on: the analysis of each case; the patient's age; type of fracture; soft skin condition; the degree of service provision; the experience of the operating team.

**Keywords:** computed tomography, reconstructive CT 3D, proximal humerus fracture, hemiarthroplasty, PHILOS

## Rezumat

În cazul fracturilor cominutive, sau al fracturilor cu deplasare a tuberozităților humerale, cazuri în care radiografiile nu sunt edificatoare, se recomandă efectuarea unei tomografii computerizate. Fracturile cominutive cu 3 și 4 fragmente afectează suprafața articulară glenohumerală și prezintă un risc important în afectarea vascularizației treimii proximale a humerusului. Osteonecroza aseptică de cap humeral este mai frecventă în urma fracturilor cominutive cu 4 fragmente. În urma radiografiilor convenționale este greu de clasificat o fractură la un pacient cu simptomatologie evidentă. În comparație cu radiografiile convenționale, tomografia computerizată cu reconstrucții 2D sau 3D evidențiază clar fractura și gradul de deplasare a fragmentelor fără suprapunere. În completare pot fi evidențiate informații despre deplasarea fragmentelor, impactarea, gradul de cominție și subluxația. În acest studiu dorim să evaluăm și să comparăm rezultatele și beneficiile utilizării tomografiei computerizate: corectarea erorilor unui diagnostic inițial; diagnostic de precizie, o clasificare de mare acuratețe a fracturilor de treime proximală de humerus, fiind de un real folos în planingul preoperator; necesitatea vizualizării directe în spațiu a realinierii fragmentelor

<sup>1</sup> Department of Orthopedy and Traumatology, „Dr. Carol Davila” Central Military Emergency University Hospital Spitalul Universitar de Urgență Militar Central, Clinica Ortopedie și Traumatologie

<sup>2</sup> „Carol Davila” University of Medicine and Pharmacy, Bucharest, Romania

<sup>3</sup> General Secretary of Romanian Academy of Medical Science, Bucharest, Romania

### Corresponding author:

**Razvan Nicolae Turcu**

“Carol Davila” University of Medicine and Pharmacy, Bucharest, Romania.

E-mail: razvan\_turcu@yahoo.com

fracturare, fapt care reduce timpul decizional intraoperator pentru evoluția ulterioară a cazului. Reușita tratamentului depinde de: analiza fiecărui caz în parte; vârsta pacientului; tipul fracturii; starea părților moi; gradul de dotare a serviciului; experiența echipei operatorii.

**Cuvinte cheie:** tomografie computerizată, reconstructive CT 3D, fractura humerus proximal, hemiartroplastie, PHILOS

## INTRODUCTION

Proximal humerus fractures result from indirect trauma, are associated with osteoporosis, and are classified into: humeral head fractures, anatomical cervical fractures, trochiter, trochin, surgical neck, or proximal diaphysis. Types of fracture and displacement are determined by the position of the humerus at the time of trauma, bone quality and the direction of muscle forces on fractured fragments<sup>1,2</sup>. Fractures with two, three or four shifted parts require surgical treatment. The dislocation fractures, except for the simple trochiter fractures, should be analyzed by the orthopedic surgeon, the reduction of the dislocation will precede the treatment of the fracture. It should be emphasized that powerful damping maneuvers can move fractured fragments, so it will be preferable to reduce it under radiological control<sup>14</sup>. Two-part fractures represent 10% of the total proximal humeral fracture. The displaced fractures of the surgical neck can affect the brachial plexus and the axillary artery due to the proximal relations in the anterior with the humeral head and the surgical cervix<sup>1</sup>. The small trochanter fractures are uncommon. A four-part fracture is a joint fracture, and the fractured fragment is shifted by the two tuberosities and the humeral diaphysis. A classical fracture with four fragments is a fracture-dislocation, in which the articular

fragment exits before, without the insertion of soft parts. It presents an important risk of osteonecrosis. The four-part fracture fracture in valgus has a better prognosis due to the preservation of vascular sources<sup>2</sup>. Following conventional radiographs, it is difficult to classify a fracture in a patient with obvious symptoms. Compared to conventional radiographs, computerized tomography with 2D or 3D reconstructions clearly shows the fracture and the degree of displacement of fragments without overlapping. In addition, information about fragment shifting, impact, coincidence, and subluxation can be highlighted<sup>4</sup>. Different 3D techniques have proven effective in diagnosing various pathologies and for preoperative planing in musculoskeletal disorders. For 3D processing, 3 different algorithms are used<sup>4</sup>. Osteoporosis is the most common cause underlying skeletal affections. Class 1 or postmenopausal oste-

### Sex distribution

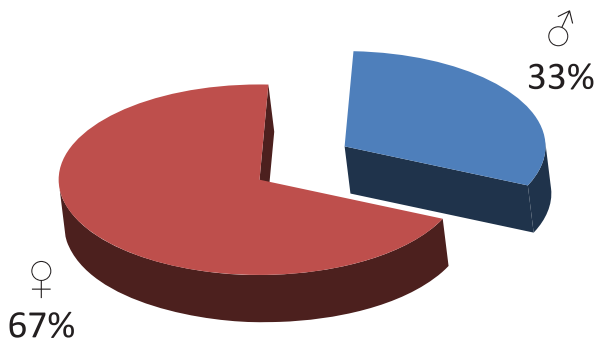


Figure 1.

### Age distribution

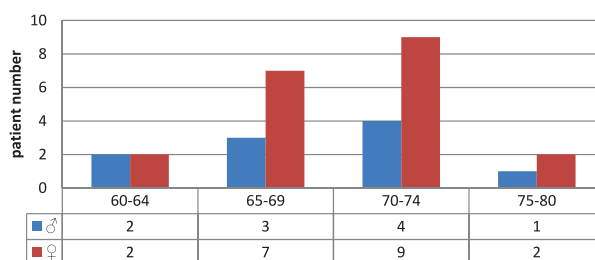


Figure 2.

### Implant type

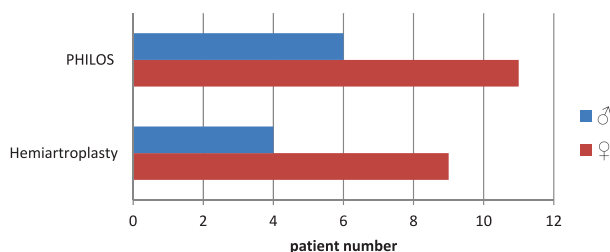
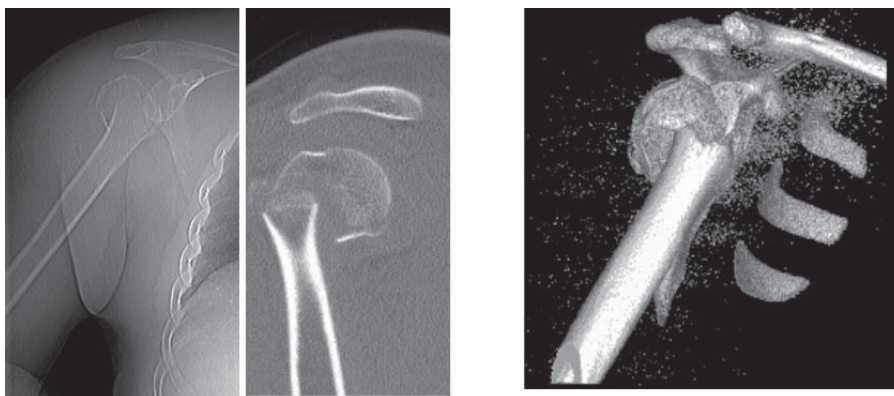
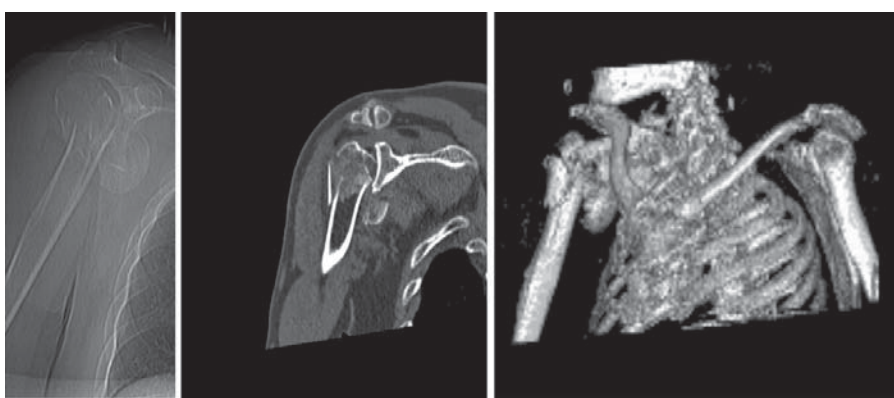


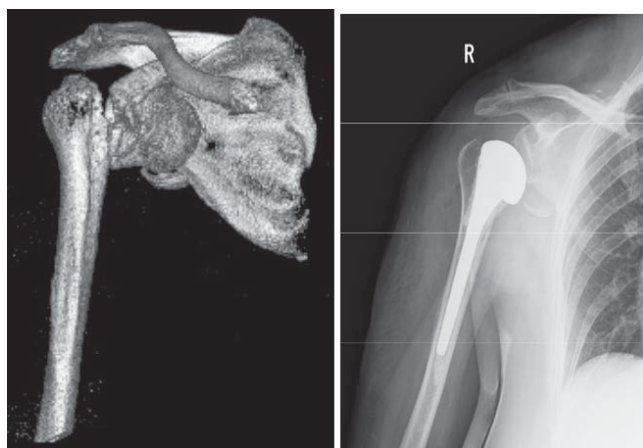
Figure 3.



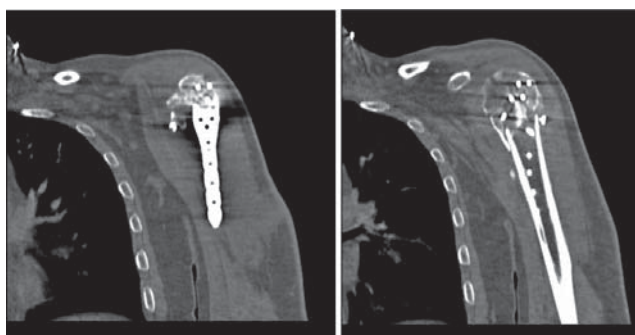
**Figure 4.** Antero-posterior radiography, CT section, 3D reconstruction of computed tomography.



**Figure 5.** Antero-posterior radiography, CT section, 3D reconstruction of computed tomography.



**Figure 6.** 3D reconstruction of computed tomography, radiographic check post hemiarthroplasty right shoulder.



**Figure 7.** CT sections, postoperative control following Phylos osteosynthesis.

oporosis or type 2 senile osteoporosis was classified. Galanger in 1990 added a type 3 as secondary osteoporosis. Postmenopausal osteoporosis usually affects women between 50-65 years of age. Accelerated trabecular bone resorption in relation to estrogen deficiency, and fractures in this group are usually located in the spine and the carpal tunnel. In senile osteoporosis the cortical, trabecular bone is affected. Fractures of senile

osteoporosis are in the hip, proximal humerus and tibia, and pelvis in people over 75 years of age<sup>5</sup>.

Although some authors assessed the effect of imaging such as computed tomography and 3D reconstructions, the results were not conclusive and there was no correlation between classifications and treatment recommendations of experienced physicians. Fractures with 4 parts showed the same treatment and classification preferences. Data showed statistical significance for 3D reconstruction more important than computed tomography and more relevant than conventional radiographs<sup>6</sup>. Treatment of proximal humerus fractures is difficult in

osteoporotic fractures. The incidence of these fractures is increasing and the literature of the last 10 years shows new methods for fractures of 2.3 or 4 parts. The increase in the number of osteoporotic fractures and the requirements for better postoperative recovery, new methods and implants have been devised. Using blocked plates, blocked centromedullary stems and humerus plaque blade, degradations of these mounts have been reported. Biomechanical studies have shown that osteoporotic bone tolerates elastic implants better than rigid ones, and with microarrays the fracture remains stable and callus formation progresses<sup>13,15</sup>. On the other hand, rigid, although very stable mechanical implants cannot be elastically deformed during movements. They can pass through the soft bone, causing degradation of the assembly and degradation of the remaining bone stock<sup>15</sup>.

Surgery is indicated in proximal humerus third fractures in case of articular instability or marked movement of fractured fragments. The choice between osteosynthesis and arthroplasty is still debated and depends on the quality of the bone and the risk of osteonecrosis of the humeral head. Osteonecrosis occurs in the case of fracture-dislocation but is closely related to the type of fracture that poses the joint and the vascular joint lesion<sup>1,8</sup>.

## MATERIAL AND METHODS

In this study we want to evaluate and compare the results and benefits of computerized tomography: correcting the errors of an initial diagnosis; precise diagnosis, a high accuracy classification of proximal third humerus fractures, being of real use in preoperative planning; The need for direct spatial visualization of the realignment of fracture fragments, which reduces the intra-operative decision-making time for the subsequent evolution of the case.

In order to achieve our research goals, we used a group of 30 patients (20 women, 10 men) with age 60 to 80 years old (age distribution chart) treated at the Clinic of Orthopedics and Traumatology at the "Carol Davila" Central University Emergency Hospital Bucharest, January 1, 2015 - January 1, 2017, without associated serious conditions, both sexes being included. The diagnosis was based on the analysis of conventional radiographs, computed tomography and 3D reconstruction in some cases. The exclusion criteria are: patients outside the age group, with associated serious pathology, or patients who refuse surgical treatment.

Surgical treatment involved reduction and osteosynthesis with blocked PHILOS (Proximal Hu-

meral Interlocked Osteosynthesis) in 16 cases and hemiarthroplasty in 14 cases (implant type chart). The basics of 2D and 3D reconstructions are subject to the appropriate acquisition protocols. Single slice computerized tomography is deficient in axial plane resolution, x-y axes, which is a major function and geometry detector, and the longitudinal resolution z-axis which is a function of the slice thickness analyzed. To generate an isotropic volume in the case of non-isotropic data, interpolation methods may be necessary. After introducing multiple CT in 1992 with dual-slice scanners, this technology was improved in 1998 with four slides, and in 2000 with 8 slides, in 2002 16 slides, in 2004 64 slice. Continued development after 2006 allowed the first 64 slice, with two sources, with a very high temporal and spatial resolution. Observing the 2-year cycle in the development of a new computer tomograph. In order to produce reconstructions, the primary source of slides of 0.5 mm to 0.125 mm thickness depending on the computed tomograph used is rebuilt, and scanning and display filters are adapted to the size of the scanned region. In order to benefit from these capabilities, the 2D and 3D reconstructions have become an integral part of the musculoskeletal and vascular examination. Sections of the same image quality as the source can be obtained in any plan. The location of the examined region becomes less important because any plan can be reformatted after scanning. This ability reduces the difficulty of examining polytraumatized patients in particular<sup>4</sup>.

X-ray images of the shoulder show the difference between internal rotation and external rotation. In internal rotation, the appearance of the humeral head is similar to a sphere; In external rotation, the trochiter can be very well highlighted. These two incidents may usually be sufficient to exclude a fracture. A dislocation may be difficult to exclude without other incidents. In the axillary and scapular incidence of the shoulder, the clavicle and the anterior acromion and the acromioclavicular joint and the glenohumeral joint can be highlighted. Due to the projection of axial radiography, anterior and posterior luxations can be easily highlighted. Another way of showing the shoulder in a plane perpendicular to the anteroposterior projection is called radiography in Y. In this patient it is oblique and a lateral shoulder radiography will be obtained. The Y-rod is represented by the body of the shoulder, while the two branches of the Y are the acromion and the coracoid process. At the center Y there is a circle corresponding to the glenoid fossa. The humeral head should be designed at the confluence of the three arms of Y. If the humeral head is posterior to the intersection



of the Y arms, a posterior dislocation can be diagnosed. Posterior luxation may appear normal in the anterior-posterior incidence. The scapular Y incidence is not as useful as the lateral axillary incidence to diagnose a dislocation or subluxation<sup>16</sup>.

Treatment of 4-part fractures was established following the evaluation of computed tomographies. These data may suggest that 4-part complex fractures can be improved under 3D reconstructions. Computed tomography allowed identification of fractured fragment numbers. In the literature, the differences in fracture classification and interpretation of imaging cause imprecise measurements of the anatomy of the affected segment. Neer described the clinical variability, the procedure and the patient as the causes of inaccurate measurements. It is important to recall that fracture classification with 4 fragments is not a radiological system, but it is an anatomopathological classification of displaced fractures. Difficulties have been demonstrated in classifying 3D images displayed on a 2D screen<sup>6</sup>. Issues that occur at the time of treatment include fracture type, bone quality, and general condition of the patient. Several methods of treatment: conservative, various forms of osteosynthesis and hemiarthroplasty have been proposed but long-term results have not been satisfactory, so the interest in finding better therapeutic solutions has been highlighted in recent years. Placing the blocked plates with higher stability has improved the fixation results. The dilemma between rigid or elastic implants in these fractures is still unresolved<sup>15</sup>. Anatomical or reversed arthroplasty is usually indicated in elderly patients, but it is a last resort treatment in younger patients in whom reduction and osteosynthesis is the treatment of choice. Computed tomography is a key in preoperative planing. Analysis of computerized tomography details is important to establish the reduction procedures that are required during surgery to achieve the reduction and osteosynthesis of all fragments<sup>8</sup>.

## RESULTS

The success of the treatment depends on: the analysis of each case; age of the patient; type of fracture; soft skin condition; the experience of the operating team.

A lipohemarthrosis may be visible as a lower-level fluid at the acromial process, an important haemarthrosis can move the lower humerus head resulting in pseudo-subluxation. An anterior or posterior subluxation or subluxation will be sought<sup>14</sup>.

High-resolution reconstruction of computed tomography provides data that allow description of un-

derlying articulation and anatomy<sup>3,4</sup>. Multi-slice computerized tomography is extremely sensitive to fracture detection, and reconstruction can highlight the spatial relationship of fractured fragments in complex anatomical regions<sup>4</sup>.

In 3-part fractures, computerized tomography was useful in determining the direction of the bolts, and postoperatively the degree of reduction and position of the implants in the humeral head was confirmed. The presence of titanium, which is an osteoinductive factor, can play an important role. In most fractures, anatomical reduction of fragments could not be assured but did not affect functional outcomes. Improving minimal invasive techniques through 3D real-time imaging of fracture and instrumentation for reduction are a breakthrough. Early functional treatment has allowed patients greater mobility despite moderate movements<sup>15</sup>.

The degradation of the assembly in the glenohumeral joint leads to degradation of the articular cartilage, resulting in unsatisfactory results and requires restoration of the glenoid surface if arthroplasty is required. The lack of consolidation of tubers due to inappropriate shunt-associated attachment may compromise subsequent arthroplasty. Bone quality analysis is required before osteosynthesis. On standard X-rays, osteoporosis is evidenced by diminishing the humeral head density, tuberositis and a low corticomedullary index of humeral diaphysis. Osteopenia highlighted in the tuberosities and displaced fragments are assessed using preoperative computed tomography. Avascular necrosis of the humeral head is a common complication, and the viability of the humeral head implies surgical strategy<sup>10</sup>. The three-dimensional reconstruction of computed tomography shows the shape and position of the fragments to determine the appropriate surgical approach. A comparison of 2D tomography diagnosis in combination with 3D reconstruction was performed with partial and complete fractures. Classification was reproduced better after 3D reconstruction. More fragments were identified than conventional imaging. 3D reconstructed computed tomography helps the surgeon to view all of the fragments and to choose the appropriate surgical approach to the type of fracture<sup>11</sup>.

## DISCUSSIONS

With regard to shifted fractures, the initial treatment involves good anesthesia, analgesia and immobilization in a toraco-brachial scarf or bandage in case of a displacement a support scarf is recommended; The bandage allows a gravitational support

of an angular deformation. The patient should be encouraged to perform passive movements, followed by active movements at the time of callus<sup>14</sup>. By evaluating the number of fragments and the parts involved: the head, the trochiter, the trochin and the diaphysis, Neer classifies the proximal fractures of the humerus in one, two, three and four parts. Each of the four locations is a fragment that is considered shifted if the distance is greater than 1 cm or rotation greater than 45 degrees. A minimal travel can be considered as leaving aside the number of fractures. The musculature inserted in the proximal third of the humerus influences the movement of the fragments. The large pectoral moves the antero-medial humeral head, the supraspinatus and infraspinatus muscles move the postero-superior tuberosity, and the subcapularis muscle pulls the medial trochin. At the time of describing the proximal humeral third fractures, it is important to specify the type with one, two, three or four fragments or anatomical or surgical collar and the fragments involved trohin, trochite or diaphysis<sup>1</sup>. According to Neer's classification, fractures of the proximal third of the humerus with a fragment are 80% of the surgical neck. Undefined fractures of the surgical neck usually have a good prognosis due to the preservation of the humeral head. In contrast, fractures of the anatomical cervix heal more severely due to vascular damage, which will develop avascular necrosis of the humeral head and secondary arthrosis<sup>2</sup>. Classification of complex intra-articular fractures is not sufficient in conventional radiographs. Also, computerized axial tomography may be difficult to interpret regions with complex anatomy. For example, locating the surfaces of the underlying joint may be difficult to interpret in the axial sections<sup>4</sup>. The first application of 3D reconstruction was in the assessment of skeletal fractures and the preparation of orthopedic surgery. A precise classification and understanding of the fractures are the basis of conservative treatment, and appropriate surgical intervention<sup>4</sup>.

Preoperative fracture planning in regions with complex anatomy, such as the shoulder and spine, the radio-carp joint may also be improved by 3D reconstruction<sup>4</sup>.

The callus at the level of fracture was evaluated on radiographs or computed tomography. Fracture reduction was anatomical<sup>8</sup>.

Shoulder rotations or other complex movements and muscle contractions, muscle dysfunction and impact on joint mechanics can be evaluated. Compared to single-sliced CT, multi-layered CT has highlighted three-dimensional aspects that are comparable to 3D reconstruction of images<sup>4,7</sup>.

## CONCLUSIONS

Although MPR - multiplan reconstructions allow for the evaluation of fragment shifts, it can not display a global view of the lesions. That's why surgeons prefer 3D reconstruction for preoperative planing. 3D imagery allows the assessment of complex fractures, but they can fail in the recognition of minimal movement fractures and subchondral lesions. Images can also highlight stepped artefacts. Volumetric interpretation was not superior to minimal shifts of fractures, especially those axially oriented. Complex lesions and spatial information about the positions of the relative fragments are highlighted as clauses. The 3D reconstruction of computed tomography can precisely delineate the spatial relationship between the fragment and the musculoskeletal structures and produce a 3D presentation of the articulation biodynamics<sup>4</sup>.

The risk of osteonecrosis appears lower in valgus impacted fractures with 4 fragments, or with 3 fragments, although osteonecrosis has also been reported in the case of displaced fracture of large tuberosity<sup>8</sup>.

Hence, the humeral head viability is a major factor in choosing the proximal humeral fracture fixation technique<sup>10</sup>.

Three-dimensional imaging is useful in preoperative planning, in determining the surgical approach and the location of the screw insertion<sup>4</sup>.

Computerized tomography is available in most emergency centers and provides an exact look for articular fractures. A newly introduced technique is 3D reconstruction derived from 2D computerized tomography. This technique has been shown to improve the diagnosis of humeral fractures<sup>12</sup>. Particularly in complex fractures affecting the articular surface, VR reconstruction with segmentation allows the evaluation of the extent of displacement of fragments that is usually undetectable in conventional radiographs, and allows a classification and a diagnosis of the fracture<sup>4</sup>.

## References

1. Ifrim Mircea; Niculescu,Gheorghe; Precup Cris; Teodora Olariu; ZsolGyori; Csongor, Toth; Ovidiu, Bulzan; Adrian, Barbilian; Stanescu Casiana; Sanda Deme; Ovidiu Hategan. Compendiu de Anatomie Topografica, Clinica si Functionala; Vasile Goldis: Arad: 2014 ISBN: 978-973-664-734-5 Pag.745: 384
2. Jorge A. Soto, Brian C. Lucey, EMERGENCY RADIOLOGY: THE REQUISITES ISBN: 978-0-323-05407-2 Copyright © 2009 by Mosby, Inc., an affiliate of Elsevier, Inc
3. S. Osiceanu, M. Dascalu, A. Barbilian, Intelligent interfaces for locomotory prosthesis - 2009 International Joint Conference on Neural Networks, Atlanta, Ga, USA, June 14-June 19, ISBN: 978-1-4244-3548-7
4. E. Neri, D. Caramella, C. Bartolozzi (Eds.) Image Processing in Radiology,2008, ISBN 978-3-540-25915-2 Springer Berlin Heidelberg New York
5. S. Grampp (Ed.) Radiology of Osteoporosis 2nd Revised Edition ISBN 978-3-540-25888-9 2008 Springer-Verlag Berlin Heidelberg
6. Abtin Foroohar, Rick Tosti, John M Richmond, John P Gaughan and Asif M Ilyas, Classification and treatment of proximal humerus fractures: inter-observer reliability and agreement across imaging modalities and experience, Foroohar et al. Journal of Orthopaedic Surgery and Research 2011, 6:38
7. P. L. Milea, G. Stefan, M. Moga, A. Barbilian, S. Mitulescu, E. Cernat, O. Oltu, C. Moldovan, S. Pompilian, Hardware & Software Package for Locomotory Disabled Patients Training, INTERNATIONAL JOURNAL of SYSTEMS ENGINEERING, APPLICATIONS AND DEVELOPMENT, Issue 1, Volume 5, March 2011, pp. 436-443, ISSN: 2074-1308
8. H. Thomazeau, J. Richoub, T. Benkalfalte, G. Kerhousse, D. Le Nenb, D. Veillard, Is it worth fixing proximal humeral fractures at increased vascular risk? Orthopaedics & Traumatology: Surgery & Research (2012) 98, 383–389
9. Eduard Franti, Lucian Milea, Monica Dascalu, Paul Schiopu, Adrian Barbilian, Marius Moga, Florin Lazo, Mark Edward Pogarasteanu, Personalized support system for the patients with forearm amputations, acceptata pentru publicare in ROMJIST (IS),Vol 15, nr.4
10. T.M. Gregory, E. Vandenbusschea, B. Augereau, Surgical treatment of three and four-part proximal humeral fractures, Orthopaedics & Traumatology: Surgery & Research (2013) 99S, S197–S207
11. T. Bégué, Articular fractures of the distal humerus, Orthopaedics & Traumatology: Surgery & Research 100 (2014) S55–S63
12. A. Jacquot, N. Poussange, J.-L. Charrissoux, P. Clavert, L. Oberte, L. Pidhorzf, F. Sirveaux, P. Mansatf, T. Fabreb, Usefulness and reliability of two- and three-dimensional computed tomography in patients older than 65 years with distal humerus fractures, Orthopaedics & Traumatology: Surgery & Research 100 (2014) 275–280
13. Eduard Franti, Lucian Milea, Verona Butu, Suzana Cismas, Mihai Lungu, Paul Schiopu, Adrian Barbilian, Anca Plavitu, Methods of Acquisition and Signal Processing for Myoelectric Control of Artificial Arms, ROMANIAN JOURNAL OF INFORMATION SCIENCE AND TECHNOLOGY Volume 15, Number 2, 2012, 91–105
14. Erskine J. Holmes, Rakesh R. Misra, A–Z of Emergency Radiology, Greenwich Medical Media Ltd 2004 isbn-13 978-0-511-21584-1
15. Wieslaw Pospula Tarek Abu Noor, Hackethal Bundle Nailing with Intramedullary Elastic Nails in the Treatment of Two- and Three-Part Fractures of the Proximal Humerus: Initial Experience at Al Razi Hospital, Kuwait, Med Princ Pract 2009;18:284–288
16. Harjit Singh, Janet A Neutze, Radiology Fundamentals Introduction to Imaging & Technology Fourth Edition ISBN 978-1-4614-0943-4 © Springer Science+Business Media, LLC 2012 Springer.