

Surgical Technique

Intraoperative Monitoring of the Recurrent Laryngeal Nerve During Thyroidectomy

Răzvan Hainăroșie^{1,2}, Octavian Ceachir¹, Mura Hainăroșie¹, Irina Ioniță¹,
Cătălina Pietroșanu², Carmen Drăghici², Viorel Zainea^{1,2}

¹University of Medicine and Pharmacy "Carol Davila", Bucharest, Romania

²Institute of Phonoaudiology and Functional ENT Surgery - Prof Dr Dorin Hociota, Bucharest, Romania

REZUMAT

Monitorizarea intraoperatorie a nervului laringeu recurent în cadrul tiroidectomiilor

Obiective: În cursul disecției glandei tiroide, una dintre cele mai importante complicații ce pot surveni este lezarea nervului laringeu recurent. Monitorizarea intraoperatorie a nervului laringeu recurent în cursul tiroidectomiilor este o tehnică menită să ajute chirurgia să identifice și să protejeze nervul.

Metodologie: Utilizarea monitorului pentru nervul laringeu recurent ajută la scăderea riscului de lezare a nervului, față de controlul oferit doar de vizualizarea directă a nervului. Anumite aspecte ale tipului de anestezie trebuie luate în considerare deoarece pot apărea artefacte sau rezultate false.

Concluzii: Scopul prezentei lucrări este de a analiza eficacitatea acestei metode, de a oferi un protocol de monitorizare care să ducă la scăderea ratei de rezultate false și de a proteja nervul laringeu recurent.

Cuvinte cheie:

ABSTRACT

Objectives: During the dissection of the thyroid, one of the most important complications that may occur is or could be the injury of the recurrent laryngeal nerve. Intraoperative monitoring of the recurrent laryngeal nerve during thyroidectomy is a technique designed to help the surgeon identify and preserve the nerve.

Methodology: The use of the monitor for the recurrent laryngeal nerve can help diminish the risk of nerve injury, when compared with the control offered by the visualization of the nerve alone. Certain aspects concerning the anesthetic act must be taken into consideration, as interactions or false results may occur.

Conclusions: The aim of the paper is to analyze the effectiveness of this technique, to provide a monitoring protocol designed to diminish false monitoring results and to secure the laryngeal recurrent nerve.

Key words: recurrent laryngeal nerve, monitoring, thyroidectomy, vocal fold palsy

Following thyroidectomy, the preservation of the recurrent laryngeal nerve is the gold standard. Visual identification of the recurrent laryngeal nerve is mandatory during thyroidectomy. That technique has decreased the

rate of permanent palsy during thyroid or parathyroid surgery (1). However, the palsy can occur when using only the visualization of the nerve, even in experienced hands (2).

Corresponding author:

Dr. Mura Hainăroșie

7 -15 Mendeleev Str., Sect 1, Bucharest, Romania e-mail: mura@riacclinic.com

Intraoperative nerve monitoring is a common technique in ear surgery, used to permanently monitor the facial nerve. This technique can be used in the thyroid surgery as well. Intraoperative neuromonitoring of the recurrent laryngeal nerve represents an adjuvant technique, until the visual identification and functional confirmation of the nerve.

The technique was not designed to replace the visual identification of the nerve. Sometimes, when we are dealing with a complex pathology, the orientation into the neck anatomical structures can be challenging even for experienced surgeons (3).

Nerve injury can be an important complication concerning the quality of voice, or even concerning the breathing, in the bilateral injury of the nerve (4). For professional voice users the impact of the nerve injury is critical.

The frequency of the permanent paralysis of the recurrent laryngeal nerve in experienced surgeons is less than 2%. The low complications rate reported in the literature seems to be much higher because inexperienced centers will not publish the paralysis rates and only in 10% of the cases the lesions are evident intraoperatively (5). The standard protocol does not imply a postoperative fiber optic exam in order to determine the functional result after surgery (6).

Intraoperative identification (that associates the following rates: transient paralysis - 3%, permanent paralysis 1%) of the recurrent laryngeal nerve seems to provide the surgeon with a much lower incidence of nerve injury than non identification of the nerve (with the following rates: transient paralysis - 9%, permanent paralysis 5%).

The anatomy of the recurrent laryngeal nerve is variable (7). The most examined is the relationship between the inferior thyroid artery and the recurrent laryngeal nerve. Anatomical studies have showed up to 28 anatomical patterns of the relationship nerve - artery.

The course of the nerve in the tracheoesophageal groove is not a reliable and constant landmark. On the left side that relationship is constant, on the right side, however, it is more variable.

Extra laryngeal branching of the recurrent laryngeal nerve occurs in 20 to 95% of the cases. Careful dissection and exposure of the extra laryngeal branches is mandatory in order to avoid nerve injury (8).

The laryngeal recurrent nerve is most prone to injury in the last 2 cm of its course. Large sub sternal goiters, thyroiditis, Graves's disease, revision surgery, thyroid cancer or previous radiation therapy can cause a difficult dissection, thus modifying the anatomy and making the identification of the nerve more difficult (9).

Intraoperative monitoring is a technique that helps the visual identification of the nerve alone (10). Numerous studies have showed that intraoperative monitoring of the recurrent laryngeal nerve will reduce the rate of

nerve injury compared with the visual identification technique alone (11).

The monitoring technique consists of using the nerve monitor system (**Fig. 1**). A special intratracheal intubation tube is used. That tube will have a set of electrodes that will come into contact with the vocal folds. Intraoperative laryngeal nerve monitoring will have some features related to the type of anesthetic used for the management of the endotracheal intubation (12).

The technique can be used based on inhalation anesthetics (sevoflurane, desflurane, isoflurane) and intravenous anesthesia techniques (TIVA) with propofol and an opioid (remifentanyl, sufentanyl or rarely, fentanyl). Inhalation anesthetics, opioids, benzodiazepines, barbiturates and propofol do not interfere with the EMG monitoring.

Intraoperative particularities of the anesthetic act are mostly related to neuromuscular dynamics. For nerve monitoring it is imperative for the neuro-muscular junction to be fully functional when the monitor is used (13). This goal becomes achievable as follows:

- practicing laryngoscopy and endotracheal intubation maneuvers using relaxing drugs with a very short or short-acting duration (e.g., succinylcholine or mivacurium) and allowing a spontaneous reversal of their effect before initiating EMG monitoring. Monitoring the depth of the neuro-muscular blockade (e.g. TOF Watch) becomes mandatory in these cases.
- complete avoidance of the muscle relaxant, using inhaled induction of anesthesia (sevoflurane) - rare; however, one can use intravenous propofol-opioid induction and the maneuvers may be performed at the time of maximum plasma effect of the two drugs (peak effect).

However, if you choose the latter technique, it is possible for the conditions of visualization of the glottis on laryngoscopy to be less than optimal, which makes the risk of damage to the larynx higher (14).

Often patients with a large thyroid can raise difficulties in intubation, so the safety technique of securing the airway must prevail over any other goal (15). Vigil intubation using fiberscopes after a proper local anesthesia and intravenous sedation will be performed easier if one always considers and anticipates a difficult intubation. A careful preoperative evaluation of the airways is important, as we consider necessary both a clinical examination and a fiber optic exam.

During the dissection maneuvers the surgeon can use a monopolar or a bipolar probe in order to detect the position of the recurrent nerve. The monopolar probe can detect the nerve even if it is covered in some adjacent layers of tissue. The bipolar probe can be used after you discover the nerve and the surgeon needs a confirmation concerning the functionality of the nerve. The amount of electrical current used to detect the nerve can be



NIM-Neuro® 3.0

Surgeon Name: Dr.Razvan Hainarosie
 Patient Name: XXXXXXXXXX
 Patient ID: XXXXXXXXXX
 Procedure: Thyroid with TriVantage

Report Created on: 28/05/2014 15:10

Page 1

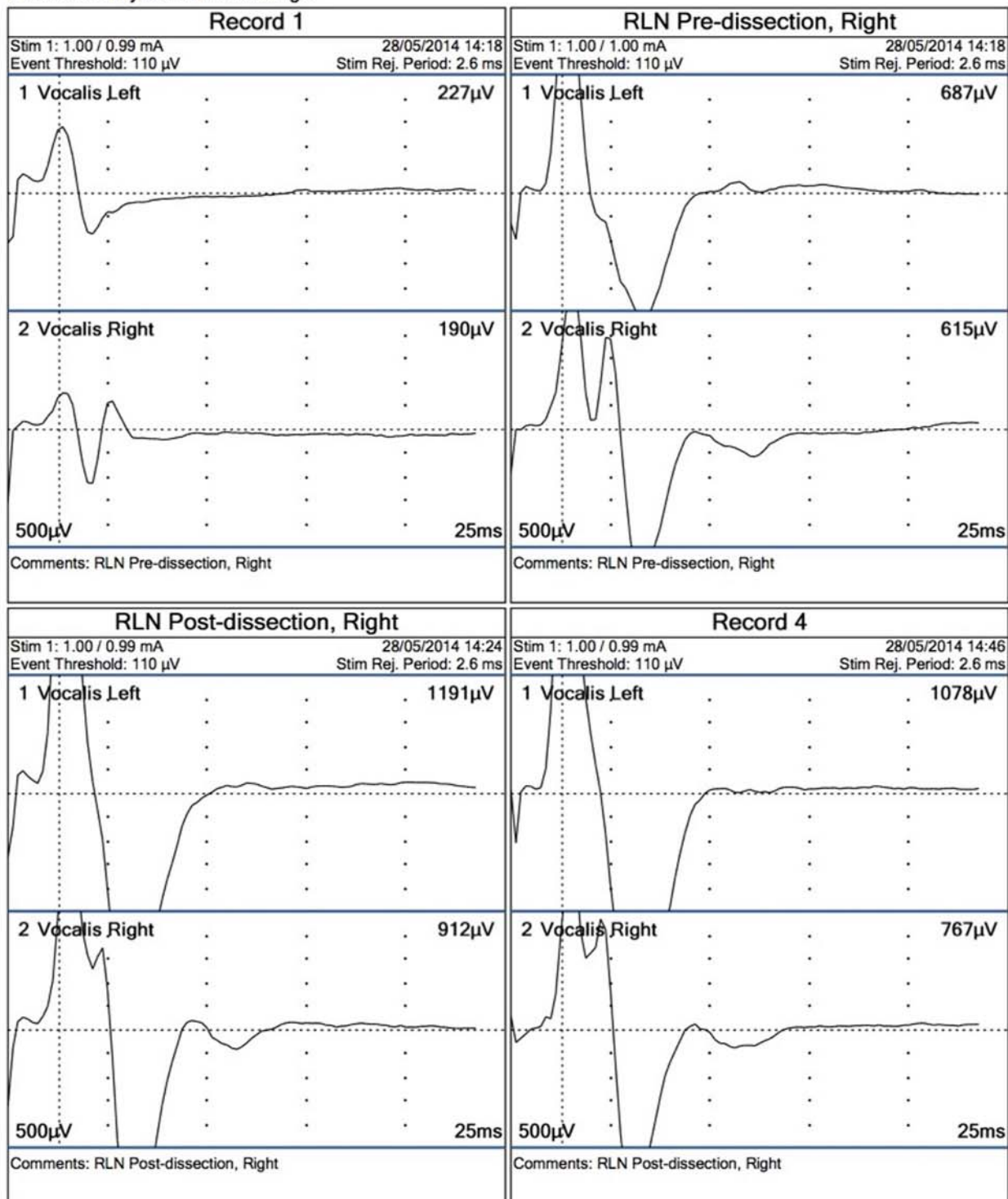


Figure 1. Intraoperative monitoring of the laryngeal recurrent nerves.

adjusted, still we recommend using minimal values between 90-120 μ V.

If the signal on the nerve monitor is abnormal, the surgical strategy regarding the contralateral part can be modified in order to avoid bilateral injury of the laryngeal nerve and tracheotomy.

Normal postoperative vocal fold mobility is not always correlated with the normal nerve monitor signal obtained at the end of the surgery. We recommend stimulating the vagus nerve rather than the laryngeal recurrent nerve, because that will ensure that the entire nervous circuit is functional. Repeated stimulation of the vagus nerve is not associated with cardiovascular or respiratory effects.

The protocol for using the nerve monitor includes:

Step 1- Preoperative videofiberoptic exam - it is necessary in order to assess the functional status of the vocal folds before surgery. It is mandatory in all cases.

Step 2 - Routine stimulation of the vagus nerve preoperatively, before surgical identification of the laryngeal recurrent nerve, which will assure that the neural circuit is fully functional. This must be the first step, before the surgical identification of the recurrent laryngeal nerve.

Step 3 - after the identification and the testing of the recurrent laryngeal nerve, testing the vagus nerve is mandatory. This will test the entire circuit and will add a prognostic value to the vocal fold movement.

Step 4 - It is mandatory to perform on every patient an early video fiber optic exam in order to observe the mobility of the vocal fold.

The intraoperative nerve monitoring technique is useful in the following cases:

- recurrent laryngeal nerve identification in the surgical field. Studies have shown that the accuracy of the method is 98 to 100%
- the monitor will guide the surgeon in the dissection of the nerve, which can be safely done even in scar tissue areas.
- from the legal point of view, the surgeon can demonstrate the intraoperative integrity of the nerve.
- an intact electromyographical signal after surgery will predict a normal function of the vocal fold.

CONCLUSIONS

We found that the intraoperative monitoring of the recurrent laryngeal nerve is an useful technique that will help the surgeon identify, dissect the nerve and predict the function of the vocal cord.

The intraoperative monitoring technique will not

replace the direct visualization of the nerve. This technology will help the surgeon confirm the position of the nerve even in a modified anatomical field.

From the legal point of view, the reports printed from the monitor will help the surgeon probe the intraoperative integrity of the nerve. In this manner, the patient can be assured of the positive results of the surgery. However, a postoperative fiber optic laryngeal exam is mandatory in order to evaluate the vocal fold's motility.

REFERENCES

1. Ready AR, Barnes AD. Complications of thyroidectomy. *Br J Surg* 1994 Nov;81(11):1555-1556.
2. Sancho JJ, Pascual-Damieta M, Pereira JA, Carrera MJ, Fontan J, Sitges-Serra A. Risk factors for transient vocal cord palsy after thyroidectomy. *Br J Surg* 2008 Aug;95(8):961-967.
3. Rice DH, Cone-Wesson B. Intraoperative recurrent laryngeal nerve monitoring. *Otolaryngol Head Neck Surg* 1991 Sep;105(3):372-375.
4. Fewins J, Simpson CB, Miller FR. Complications of thyroid and parathyroid surgery. *Otolaryngol Clin North Am* 2003 Feb;36(1):189-206, x.
5. Jatzko GR, Lisborg PH, Möller MG, Wette VM. Recurrent nerve palsy after thyroid operations—principal nerve identification and a literature review. *Surgery* 1994 Feb;115(2):139-144.
6. Steurer M, Passler C, Denk DM, Schneider B, Niederle B, Bigenzahn W. Advantages of recurrent laryngeal nerve identification in thyroidectomy and parathyroidectomy and the importance of preoperative and postoperative laryngoscopic examination in more than 1000 nerves at risk. *Laryngoscope* 2002 Jan;112(1):124-133.
7. Snyder SK, Lairmore TC, Hendricks JC, Roberts JW. Elucidating mechanisms of recurrent laryngeal nerve injury during thyroidectomy and parathyroidectomy. *J Am Coll Surg* 2008 Jan;206(1):123-130.
8. Kasemsuwan L, Nubthuenetr SJ. Recurrent laryngeal nerve paresis: a complication of thyroidectomy. *Otorhinolaryngology* 1997;26:365-367.
9. Bergamaschi R, Becouarn G, Ronceray J, Arnaud JP. Morbidity of thyroid surgery. *Am J Surg* 1998 Jul;176(1):71-75.
10. Delbridge L. Total thyroidectomy: the evolution of surgical technique. *ANZ J Surg* 2003 Sep;73(9):761-768.
11. Acun Z, Cinar F, Cihan A, Ulukent SC, Uzun L, Ucan B, et al. Importance of identifying the course of the recurrent laryngeal nerve in total and near-total thyroid lobectomies. *Am Surg* 2005 Mar;71(3):225-227.
12. Tomoda C, Hirokawa Y, Uruno T, Takamura Y, Ito Y, Miya A, et al. Sensitivity and specificity of intraoperative recurrent laryngeal nerve stimulation test for predicting vocal cord palsy after thyroid surgery. *World J Surg* 2006 Jul;30(7):1230-1233.
13. Canbaz H, Dirlik M, Colak T, Ocal K, Akca T, Bilgin O, et al. Total thyroidectomy is safer with identification of recurrent laryngeal nerve. *J Zhejiang Univ Sci B* 2008 Jun;9(6):482-488.
14. Echternach M, Maurer CA, Mencke T, Schilling M, Verse T, Richter B. Laryngeal complications after thyroidectomy: is it always the surgeon? *Arch Surg* 2009 Feb;144(2):149-153, discussion 153.
15. Mutlu D, Ramazan M. Factors Effecting Recurrent Laryngeal nerve Injury after thyroid gland surgery. *Turkiye Klinikleri J Med Sci.* 1999;19:193-199.