

Original Paper

Total Lower Lip Reconstruction – What Techniques Should We Choose

N. Calcaianu^{1,2}, S.A. Popescu^{1,2}, Daniela Diveica¹, I. Lascăr^{1,2}

¹Clinic of Plastic Surgery and Reconstructive Microsurgery, Clinical Emergency Hospital, Bucharest, Romania

²"Carol Davila" Medical University Bucharest, Romania

REZUMAT

Reconstrucția totală a buzei inferioare – Ce tehnici ar trebui să alegem

Introducere: Deși incidența cancerului de buze în Europa centrală este scăzută fiind 0,7 % din totalul tumorilor maligne, comparativ cu 1-2 % față de alte zone, această patologie este extrem de importantă din punct de vedere clinic și chirurgical datorită schimbărilor morfologice și funcționale implicate.

Materiale și metode: Am analizat posibilitățile de reconstrucție chirurgicală pentru defectele complete ale buzei inferioare și după evaluarea avantajelor și dezavantajelor am ales tehnica Camille - Bernard modificată pentru a trata o serie de 11 de pacienți cu tumori buză inferioară.

Rezultate: Am avut ca și complicații o fistulă deasupra bărbiei pentru 3 pacienți, precum și necesitatea unei revizuirii secundare a aspectului roșului buzei la 4 pacienți.

Discuții: În timp ce tehnica Karapandzic restabilește funcționalitatea mușchiului orbicular ea are și o serie de dezavantaje: apariția microstomiei, dar mai ales rezultatul estetic nesatisfăcător din cauza cicatricilor vizibile. Tehnica Camille - Bernard pentru reconstrucția buzei inferioare permite restabilirea comisurii, nu provoacă microstomie și permite reconstrucția roșului buzei cu mucoasa bucală. Dezavantajele sunt reprezentate de posibila hipoestezie și hipotonie a buzei inferioare cu incontinență salivară.

Concluzii: Pentru reconstrucția buzei inferioare atitudinea chirurgicală cea mai bună ar trebui să aibă ca scop menținerea funcționalității și a aspectului estetic al buzelor. Tehnica Camille Bernard modificată oferă o deschidere bună a comisurii bucale, nu modifică conținutul și fonația și oferă un rezultat estetic satisfăcător sau bun.

Cuvinte cheie: cancer de buză inferioară, reconstrucție totală de buză inferioară, tehnica Karapandzic, tehnica Camille – Bernard

ABSTRACT

Background: While the incidence of lip cancers incidence in the central Europe is low 0.7% of all malignant tumors compared to the 1-2% generally considered, they are extremely important from a clinical and surgical point of view because of the morphological and functional changes involved.

Corresponding author: Șerban Arghir Popescu, MD
Clinic of Plastic Surgery and Reconstructive Microsurgery, Clinical Emergency Hospital, Bucharest
e-mail: serban_arghir_popescu@yahoo.com

Materials and methods: We reviewed the possibilities of surgical reconstruction for the total lower lip defects and after assessment of the advantages and disadvantages we have chosen the Camille-Bernard modified technique to treat a series of 11 patients with lower lip tumors.

Results: We had for complications a fistula above the chin for 3 patients and the need of a secondary revision of the red aspect of the lip in 4 patients.

Discussions: While Karapandzic restores the functionality of the orbicularis muscle it also has a series of drawbacks: the appearance of microstomia, but mainly the aesthetic result is unsatisfying due to the visible scar. The Camille-Bernard technique for lower lip allows restoring of the commissure, does not cause microstomia and allows to easily rebuild vermilion with mucosa. The disadvantages are represented by possible hypoaesthesia and hypotonia of the lower lip with salivary incontinence.

Conclusions: For the lower lip reconstruction the most appropriate surgical approach to adopt should always be aimed at maintaining, the functionality and appearance of the lip. The Camille Bernard modified technique offers a good oral aperture, does not alter the oral contentment and phonation and offers a satisfactory or good aesthetic result.

Key words: lower lip cancer, total lower lip reconstruction, Karapandzic technique, Camille-Bernard technique

BACKGROUND

While the incidence of lip cancers incidence in the central Europe is low 0.7% of all malignant tumors compared to the 1-2% generally considered (2-5), they are extremely important from a clinical and surgical point of view because of the morphological and functional changes involved. More than 90% of these tumours are squamous cell carcinomas (SCCs) and, in lesser numbers, basal-cell tumours (BCCs); however, some adenocarcinomas deriving from the minor salivary glands can be observed and, even more rarely, melanomas, sarcomas and lymphomas. BCCs generally occur in the upper lip and do not usually present lymph node metastases (4, 6). In contrast, SCCs develop most often in the lower lip, with a possibility of neck metastases. Lip carcinomas frequently appear on top of pre-cancerous lesions, such as radiodermatitis, chronic chelitis and xeroderma pigmentosum. The diagnosis and treatment of these pre-cancerous lesions, facilitated by a direct view of the lesions, is, therefore, crucially important in order to avoid their evolving into actual tumours. The subjects most at risk of this type of tumour are fair-skinned elderly people who work in the open air. Men are more at risk than women, (1.3% men and 0.3% women) (1) probably because the latter use lipstick or lip-salve (2, 7-9). Other risk factors, involved in the development of the tumours are smoking, tobacco-chewing and chronic alcohol consumption. Exposure to viral

oncogenes has also been held responsible, especially in immune-depressed subjects (10, 11). The tumour, in its initial phase, usually appears as a papule or a plate which tends to progress into a vegetative or ulcerative form. In our country the lack of sanitary education seems to play a significant role in having to treat patients in stages where all the lower lip is affected by tumor lesions. Although in the case of T1 or T2 lesions, the percentage of patients with lymph node metastases, at the time of diagnosis is 8%, this figure increases considerably in advanced-stage tumours, making it necessary to search for possible cervical metastatic adenopathies (3). The diagnostic routine and the pre operative planning requires an imagistic examination such as ultrasonography, computed tomography (CT) scan and/or magnetic resonance (MR) to define the extent of the lesion and confirm any spreading to the main loco-regional lymph nodes. In tumors involving more than 1/3 of the lip resection with simultaneous reconstruction is necessary (1).

MATERIALS AND METHODS

We had made a review of the possibilities to surgical reconstruct the total lower lip defects after an oncologic margin resection (5 to 7 mm) and after assessment of the advantages and disadvantages of the surgical techniques available we have chosen the Camille-Bernard modified technique to treat a series of 11 patients with lower lip tumors.

RESULTS

In our group of patients we had for complications a fistula above the chin for 3 patients easily solved with a guided secondary healing in terms of a medium interval of 7 days and a secondary local anesthesia revision of the red aspect of the lip in 4 patients.

DISCUSSIONS

The main reconstruction techniques in full lower lip defects by using tissues from neighboring regions are Karapandzic and Camille-Bernard techniques. Karapandzic technique (11) is based on achieving certain bilateral flaps irrigated by branches of the facial artery. Skin incisions are parallel to the edge of the lip, a distance equal to the size of the tumor. It is necessary a careful preoperative marking of the incision lines, especially in the labial commissure. The technique has a number of advantages and reasons that it preserve the vascular-nervous structures of the lip, does not require redoing vermilion and it restores the functionality of the orbicularis muscle thus obtaining a proper direction of muscle fibers with restoring sphincters to prevent salivation. Application of this technique for defects larger than 2/3 of the lower lip leads to a number of drawbacks: the appearance of microstomia, commissurotomy is required in a later stage, you cannot restore the defects which are interested in the oral commissure and a slight hypoesthesia and hypotonia of the lower lip. Aesthetic result is unsatisfying due to the visible scar.

Camille-Bernard technique (12) consists of complete excision of the lower lip practicing chin tegument incisions in “W” or incisions “in barrel” that may extend outside the commissure horizontally, then two triangles are excised all over the thickness of the sides of the upper lip to advance medial two flap nasal folds. The Camille-Bernard technique (13) allows restoring of the commissure, does not cause microstomia and allows to easily rebuild vermilion with mucosa. The disadvantages are represented by possible causing hypoesthesia and hypotonia of the lower lip and sometimes salivary incontinence.

When more than full lower lip defects will result reconstruction is done using tissues from a distance, such as regional flaps. Sternocleidomastoid muscle flap (14) has the following advantages: arc of rotation and increased viability through acceptable

management of multiple nerve branches. The disadvantage is that it involves two surgical stages. An alternative to the regional flaps may be the transferred free flaps focused on radial artery presenting a series of advantages: relatively easy dissection, the possibility of intervention in two teams, operators is thin and easily folded on the receivers, featuring special features similar in texture and color with that of the lower lip. Postoperative results are good at the level of the receiver, the esthetic and functional.

Depending on the needs and motivations of the patient, but also taking into account the existing material has chosen the most suitable method for the reconstruction of the lower lip, which will give the maximum satisfaction of the patient, maintaining functional aspects of the lower lip: contention of the oral cavity, the need to repair the dental arch before recreating itself, phonation. A flap used to reconstruct the lower lip must contain the appropriate components to try to meet the functional needs of the defect to be rebuilt. The flap must meet appropriate both in terms of size, but also texture, form and color. It is also important to consider the donor area, trying to decrease morbidity and getting a better aesthetic result.

In our group of 11 patients with more than 2 thirds of the lip defect after the excision we decided to use a modified Camille Bernard technique. We used two variants of incisions on the chin teguments. A W shape incision was used when the tumor was limited. This shape of the lower border of the excision had the advantage of avoiding a single point of suture where the lateral flaps met the chin flap and therefore the incidence of the fistulas was reduced in that manner. The disadvantage of this type of excision was a visible scar on the chin without respecting the Langer minimum tension lines. The other manner in which we made the excision was a barrel line around the chin. This kind of design favored the advancement of the neck tegument under the chin and also had the advantage to place the suture according to the Langer lines, but had for disadvantage a higher rate of fistulas at the point of suture between the lateral flaps and the chin flap.

We made a choice between these two excisions after assessing the remains of the mucosa after the oncologic margin excision: if the mucosa was enough we had choose the "W" uppercase shape excision, while whenever the excision was surpassing the labial commissurae we had to use the barrel round excision.

Regarding the lymphadenectomy when the lymph nodes appeared on the MRI to be involved in the lesion the option was to do a lymphadenectomy in the same time with the lower lip reconstruction. When there were no signs of lymph nodes involvement we delayed the lymphadenectomy by a month a month and a half. Reasons for this attitude were to not prolong the surgery at usually elder patients with high anaesthetic risks and the role of filters of the lymph nodes which were able to catch the possible elements to disseminate during the surgery procedure.

CONCLUSIONS

For the lower lip reconstruction the most appropriate surgical approach to adopt should always be aimed at maintaining, the functionality

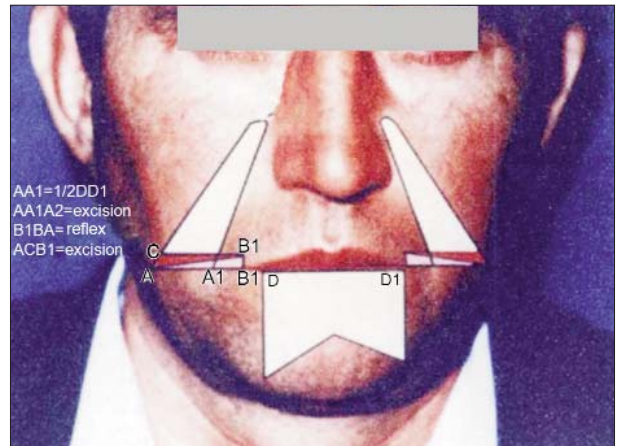


Figure 1. Modified Camille Bernard technique
 AA1A2 - the coetaneous excision triangle; A2 - the upper angle of the excision triangle; DD1 - the total length of the lower lip excision (the post excision defect will be a W or a barrel around the chin; AA1 - the inferior limit of the excision triangle $AA1 = \frac{1}{2}DD1$; A1B - the paracommissural incision on the mucosal aspect $A1B = \frac{1}{2}AA1$; AB1B - mucosal triangle for the reconstruct the red aspect of the lip; AB1C1 - surplus mucosal triangle to be excised

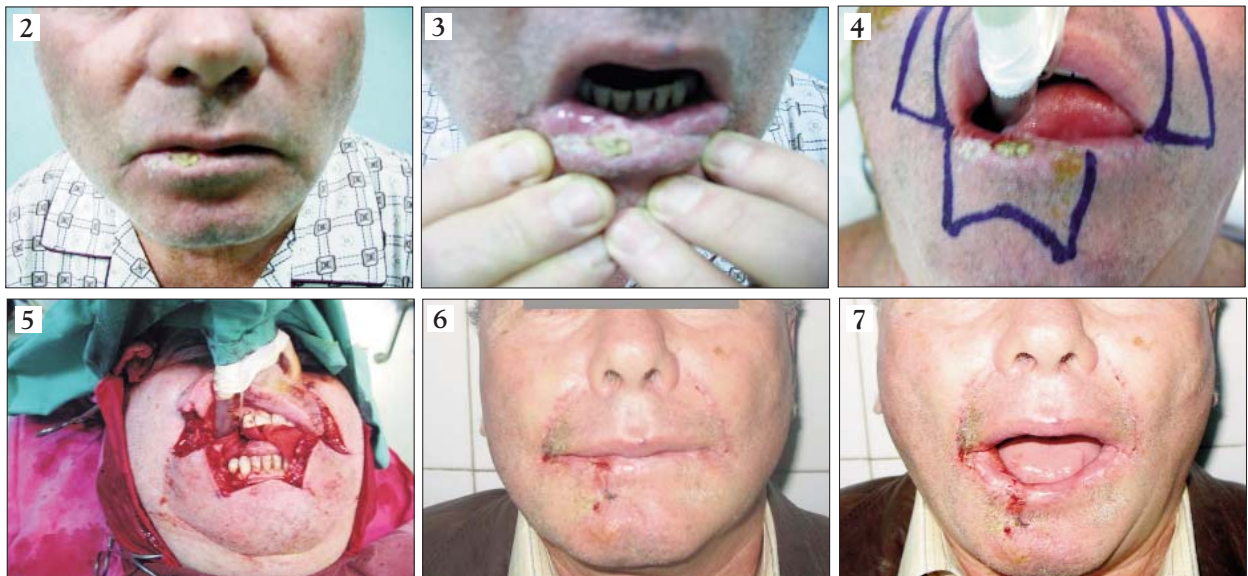

Figure 2-7. Modified Camille Bernard technique with w shape chin tegument incision

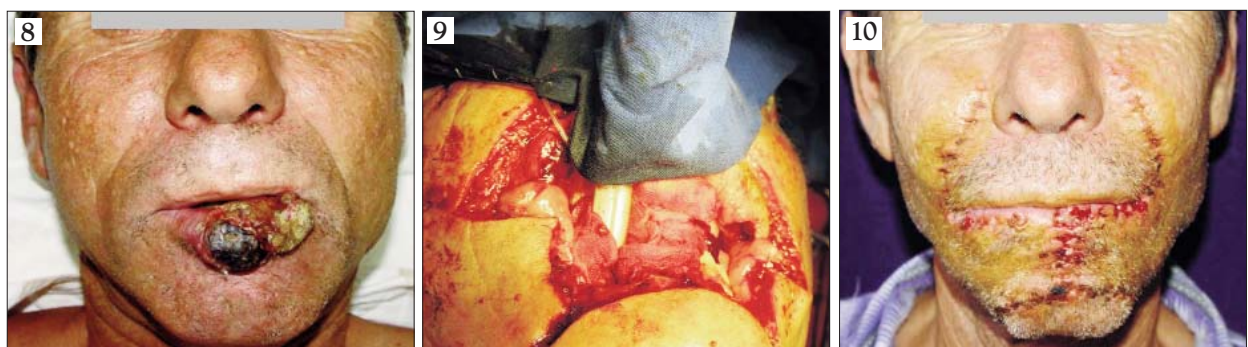

Figure 8-10. Modified Camille Bernard technique with a barrel line around the chin tegument incision

and appearance of the lip. The Camille Bernard modified technique offers a good oral aperture, does not alter the oral contention and phonation and offers a satisfactory or good result on the red aspect of the lip while other surgical scars are concealed in the natural folds of the face (the nasal genial fold) and there for we consider it as the first choice when a total lower lip reconstruction is needed. For the lymphadenectomy a super-selective neck dissection would help with precise and early metastases identification, such as sentinel lymph node, PET/CT (15) would substantially improve the patients' prognostic.

REFERENCES

1. Karcz W, Głuszek S, Szebla J Bernard-Soltan technique in surgical treatment of lower lip cancer). *Z Oddziału Chirurgii Ogólnej i Onkologicznej Wojewodzkiego Specjalistycznego Zespołu Opieki Zdrowotnej Gruźlicy i Chorob Płuc w Kielcach, Szpital Czerwona Góra. Wiadomości Lekarskie (Warsaw, Poland : 1960)* (2006, 59(3-4):189-195)
2. Baker SR. Current management of cancer of the lip. *Oncology*. 1990;4:107–120. (PubMed)
3. Vartanian JG, Carvalho AL, Araujo Filho, et al. Predictive factors and distribution of lymph node metastasis in lip cancer patients and their implications on the treatment of the neck. *Oral Oncology*. 2004;40:223–227. (PubMed)
4. Zitsch RP, Lee BW, Smith RB. Cervical lymph node metastases and squamous cell carcinoma of the lip. *Head Neck*. 1999;21:447–453. (PubMed)
5. Moore SR, Johnson NW, Pierce AM, et al. The epidemiology of lip cancer: a review of global incidence and aetiology. *Oral Dis*. 1999;5:185–195. (PubMed)
6. Khuder SA. Etiologic clues to lip cancer from epidemiologic studies on farmers. *Scand J Work Environ Health*. 1999;25:125–130. (PubMed)
7. Stucker FJ, Lian S. Management of cancer of the lip. *Operative Techniques in Otolaryngology - Head Neck*. 2004;15:226–233.
8. Papadopoulos O, Konofaos P, Tsantoulas Z, et al. Lip defects due to tumor excision: Apropos of 899 cases. *Oral Oncology*. 2007;43:204–212. (PubMed)
9. Zitsch RP. Carcinoma of the lip. *Otolaryngol Clin North Am*. 1993;26:265–277. (PubMed)
10. Galyon SW, Frodel JL. Lip and perioral defects. *Otolaryngol Clin North Am*. 2001;34:647–666.(PubMed)
11. Karapandzic M. Reconstruction of lip defects by local arterial flaps. *Br J Plast Surg*. 1974;27:93–97.(PubMed)
12. Bernard C: Cancer de la livre inferieure: restauration a l'aide de lambeaux quadrilateraux lateraux. *Querison* 5:162-64,1852
13. Herrera E, Bosch RJ, Barrera MV. Reconstruction of the Lower Lip: Bernard Technique and Its Variants. *Dermatol Surg*. 2008;34(5):648-55.
14. Owens N: Compound neck pedicle designed for the repair of massive facial defects: formation, development and application. *Plast. Reconstr. Surg*. 15:369-389,1955
15. Moretti A, Vitullo F, Augurio A, Pacella A, And Croce A: Surgical management of lip cancer. *Acta Otorhinolaryngol Ital*. Feb 2011; 31(1): 5–10.