

## Surgical Technique

# The Use of Ultrasonic Aspirator in the Surgery of the Fibrous Dysplasia Involving the Skull Base

V. Zainea<sup>1,2</sup>, M. Hainăroșie<sup>1</sup>, O. Ceachir<sup>1</sup>, Irina G Ioniță<sup>1</sup>, Andreea Sorică<sup>1,2</sup>, Cătălina Pietroșanu<sup>2</sup>, R. Hainăroșie<sup>1,2</sup>

<sup>1</sup>“Carol Davila” University of Medicine and Pharmacy, Bucharest, Romania

<sup>2</sup>“Prof. Dr. Dorin Hociota” Institute of Phonoaudiology and Functional ENT Surgery, Bucharest, Romania

### REZUMAT

#### *Utilizarea aspiratorului ultrasonic în chirurgia displaziei fibroase ce implică rinobaza*

Displazia fibroasă este o afecțiune benignă caracterizată de înlocuirea țesutului osos normal și a măduvei osoase cu țesut fibros și os spongios. Poate fi izolată la nivelul unui singur os sau poate avea localizări scheletale multiple (poliostică). Displazia fibroasă poliostică poate determina leziuni ce implică orbita, nervul optic, etmoidul și sfenoidul. În cazul leziunilor localizate în sinusul sfenoid, proximitatea și compresi pe nervul optic poate determina cecitate. În aceste cazuri este recomandată decompresia chirurgicală a nervului optic pentru a preveni producerea afecțiunii descrise mai sus. Țesutul displazic a fost înlăturat utilizând aspiratorul ultrasonic. Această lucrare prezintă avantajele utilizării acestui dispozitiv într-o zonă ce conține elemente anatomice vitale.

**Cuvinte cheie:** aspirator ultrasonic, displazie fibroasă, bază craniu

### ABSTRACT

Fibrous dysplasia is a non malignant disease characterized by the replacement of normal bone and marrow with fibrous tissue and woven bone. It can be isolated to a single bone or have multiple skeletal sites (poliostotic). The poliostotic fibrous dysplasia can develop lesions that involve the orbit, the optic nerve, ethmoid and sphenoid bone. During the development of the lesion at the level of the sphenoid sinus the compression and the proximity to the optic nerve may cause blindness. In these cases it is recommended to perform optical nerve decompression in order to prevent it. The fibrous dysplasia tissue was removed using the ultrasonic aspirator. This paper presents the advantages of using this device in an area containing vital anatomical elements.

**Key words:** ultrasonic aspirator, fibrous dysplasia, skull base

---

#### Corresponding author:

Octavian Ceachir, MD

“Prof. Dr. D. Hociotă” Institute of Phonoaudiology and Functional ENT Surgery

21<sup>st</sup> Mihail Cioranu Street, 5th District, Bucharest, Romania

e-mail: octavianceachir@gmail.com

## BACKGROUND

Craniofacial fibrous dysplasia is a non-malignant disease. It appears due to the mutations of the GNAS gene that results in inhibition of the differentiation and proliferation of bone-forming stromal cells and leads to the replacement of normal bone and marrow by fibrous tissue and woven bone. Sometimes it is isolated to a single or multiple skeletal sites and / or endocrine organ (1, 2, 3, 4).

The disease commonly progress as a slow developing mass. Distortion of optic nerve, eye ball, nasal airway, facial nerve, teeth and middle ear ossicles can occur. In young patients, at prepubertal age, the growth is rapid and can cause aneurismal bone cysts or mucocèles (1, 3, 5). The malignant change to osteosarcoma or other form of sarcoma can appear in less than 1% of cases (1, 2).

The most prudent approach is a conservative one since the growth after puberty is diminished, but in case that the fibrous dysplasia starts to develop important deformities or compressing the optic nerve, nasal obstruction or hearing impairment, posterior displacement of the tongue, an aggressive surgical resection is needed (6). The rapid growth of the lesions usually occurs in patients with excess levels of growth hormone, so it is recommended to manage the hormone levels. This paper provides clinically focused multidisciplinary management, natural progression and consideration for future research.

### Fibrous dysplasia of the paranasal sinuses

The most frequent site affected by fibrous dysplasia is the sphenoid sinus followed by the ethmoid and maxillary sinuses. In this way the anterior skull base can be involved. The entire sinus can be completely occupied by the disease, but surprisingly the incidence of sinusitis is not greater than in normal population. The most frequent symptom is nasal congestion, followed by headache, facial pain, recurrent sinusitis and hyposmia. A correlation between the nasal congestion, hyposmia and the severity of the disease is made. There is no direct correlation between the amount of craniofacial disease and the history of sinusitis, facial pain or headaches.

### Skull base disease

The poliostotic fibrous dysplasia can develop lesions that involve the orbit, the optic nerve, ethmoid and sphenoid bone. The poliostotic fibrous dysplasia located around the eyeball is commonly associated with proptosis, hypertelorism and dystopia due to involvement of the frontal, sphenoidal and ethmoidal regions. Less common findings include: strabismus, lid closure problems, nasolacrimal duct obstruction and tearing, muscle palsy and, in cases of skull base involvement, trigeminal neuralgia and optic neuropathy (7).

The management of fibrous dysplastic lesions of the sphenoidal bone that encase the optic nerve, particularly

in patients with normal vision, is a real controversy (8). During the development of the lesion the compression and the proximity will cause blindness. In these cases it is recommended to perform optical nerve decompression in order to prevent blindness. Prophylactic decompression of the optic nerve is recommended because the most common neurologic complication in this disease is the loss of vision. The bony lesion tends to grow back. Unfortunately the optical nerve decompression will not improve the vision. Some authors prefer to observe the patient, with regular ophthalmologic tests, and refer them to surgery only when symptomatology is manifested.

A significant decrease of the bony optic canal (on the CT findings) in patients with fibrous dysplasia was reported by some authors but there was no correlation between the narrowing of the optic canal and the neuro-ophthalmologic tests (8). Because of this the recommended management of the fibrous dysplastic lesions located at the level of the skull base or around delicate anatomical structures is to be a surgical one, only in cases where the symptomatology will impose an aggressive approach. If the symptoms do not impose a surgical approach, clinical examination and regular diagnostic imaging and observation is recommended.

If it is determined that the fibrous dysplasia lesions are surrounding the optical nerve and/or the orbit, an extensive ophthalmological exam is imposed. The exam will include: visual acuity, visual field exam, contrast sensitivity, color vision, fundus exam. Additional exams have to be made: movements of the eyeball, proptosis, lid closure, pupil hypertelorism and tear duct (9). The optic neuropathy diagnostic will be reserved for patients with visual field defect if two of three exams (colour vision, fundus or contrast sensitivity) are abnormal. The high resolution optical coherence tomography is a modern diagnostic modality to determine the thickness of the retinal nerve fibers. It is particular in paediatric population where the common ophthalmological exam is difficult to be performed. If the thickness of the retinal fibers is affected prior the surgery it is unlikely that the quality of the vision will be improved. A normal thickness of the retinal fibers will have a better prognostic in terms of vision improvement after the surgery.

The aetiology for the visual alteration or vision loss in the patients with fibrous dysplasia lesions remains unclear, though it seems that associated endocrinopathy are more likely to be associated in these patients. More common is the growth hormone excess. Aneurismal cysts or mucocèles can be associated with vision loss. Published studies showed that, in patients with severe fibrous dysplastic lesions, few had evidence of optic nerve neuropathy. Patients with growth hormone excess had a higher risk to develop optic nerve neuropathy. In that cases the aggressive management of the growth hormone levels will result in the prevention of optic nerve lesions.

Urgent decompression of the optic nerve will be performed in acute visual change or vision loss (10, 11). The association of new lesions nearby the optic nerve will impose surgical approach of these lesions.

### Surgical management of the fibrous dysplasia.

#### The use of ultrasonic aspirator.

The main goal in the surgical management of the fibrous dysplasia is the resection of the lesions with the complete removal of the fibrous dysplastic tissue, sparing all nerves and adjacent organs, if possible. After the resectional stage of the surgery is performed, the second step will be the reconstructive one. In case of incomplete resection of the lesions, the bony tissue may grow again.

In order to be guided about the limit of the resection and the complete resection to be achieved the computer navigation system is an important tool in the surgery of the fibrous dysplasia.

We have also used the Stryker Sonopet ultrasonic aspirator. This ablative technology is based on the vibration (piezoelectric) of the tip of the instrument. Depending on the tip of the instrument that is used the vibration range is between 25 - 34 kHz. The surgical site is continuously irrigated by the Sonopet machine and the ablated material is aspirated. So the surgeon is using one hand to hold the endoscope and the other hand to hold the Sonopet surgical hand piece that is performing the ablation, irrigation and aspiration. The irrigation will keep the temperature of the surgical site cool so osteonecrosis, due to high temperature, will be prevented.

The surgeon can choose from no more than 30 types of surgical tips that work with the hand piece. The tips have different lengths and different geometry.

The Sonopet has 5 different programs: cortical bone removal; medullar bone removal, mixt bone removal, soft tissue and auto.

The amount of irrigation can be adjusted.

We have used a long tip, of 34 MHz, for bone removal and the medullar bone program. Using the trans nasal approach we removed the fibrous dysplasia tissue from the sphenoidal and the ethmoidal sinuses (Fig. 1, Fig. 2). The surgery was done under the guidance of the computer navigation system.

The ultrasonic aspirator respects the soft tissue if the bone program is chosen. The intelligent software will stop the vibration of the hand piece if the ablative tip of the ultrasonic aspirator is in contact with nerves or arteries.

The fibrous dysplasia tissue was removed safely because it was extremely difficult to harm the optic nerve, the internal carotid artery or the brain, in case that the ablative tip of the ultrasonic aspirator came in close contact with these delicate and vital anatomical structures.

After 6 months the patient came back with an

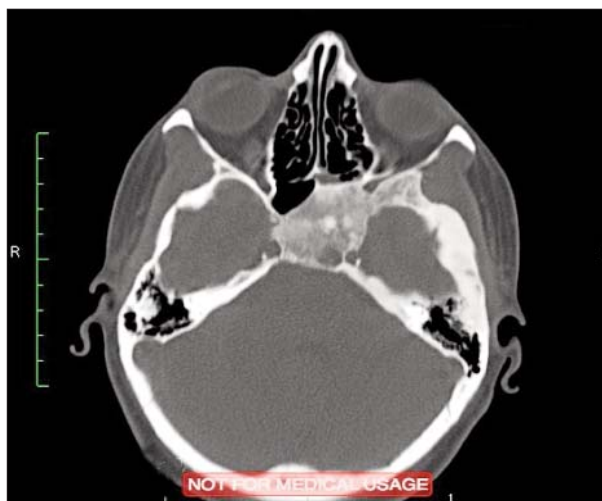


Figure 1. CT, transverse view – Spheno-ethmoidal fibrous dysplasia

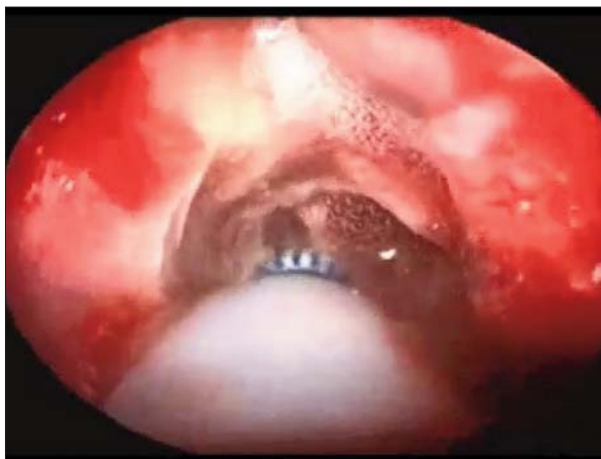

Figure 2. Endoscopic view – The ultrasonic aspirator in the right sphenoid sinus

important asymmetry of the face because of an important fibrous dysplasia lesion, located at the left arch of the mandible. That lesion was removed using the ultrasonic aspirator, set on the bone removal program. A 25 kHz tip probe was used to remove all dysplastic bone, sparing the mandibular nerve. Because the remaining bony tissue was too thin, the danger of mandibular fracture was present, so a mandibular titanium plate had to be set in place using titanium screws. The osseointegration of the plate was normal.

The follow up at one year revealed that the sphenoid and ethmoidal sinuses were disease free. The patient is followed up yearly. The symptoms (headache) disappeared after surgery. No bisphosphonates were administered.

### CONCLUSION

The ultrasonic aspirator is a useful and safe tool in the surgery of the fibrous dysplasia lesions located in the

paranasal sinuses or the skull base.

The ultrasonic aspirator will help the surgeon to safely remove the pathological tissue in small and hidden areas of the sphenoid and ethmoid sinuses, nearby the skull base and orbit, without harming delicate and sometimes vital structures such as internal carotid artery, optic nerve or brain. The hand piece will ablate, irrigate and aspirate in the same time and that is a great advantage in endoscopic sinus and skull base surgery, where the surgical site is limited.

The goal of surgery in fibrous dysplasia is complete removal of the pathologic tissue and the ultrasonic aspirator helps the surgeon to safely achieve this.

The ultrasonic aspirator can be used in the orthognatic surgery or to remove other fibrous dysplasia lesion in poliostotic fibrous dysplasia cases, without harming the nerves or vessels.

The continuous irrigation of the surgical site will permit the bony lesion removal without osteonecrosis due to high temperature.

The speed of bony removal by using the ultrasonic device is greater than that of a surgical drill. The continuous aspiration and irrigation make the ultrasonic aspirator a suitable tool for tissue removal using a transnasal endoscopic approach.

All these qualities make the ultrasonic aspirator a useful tool mainly for bony tissue removal in the endoscopic surgery of the sinuses and skull base.

## REFERENCES

1. Edgerton MT, Persing JA, Jane JA. The surgical treatment of fibrous dysplasia. With emphasis on recent contributions from cranio-maxillo-facial surgery. *Ann Surg* 1985; 202(4):459-479.
2. Sadeghi SM, Hosseini SN. Spontaneous conversion of fibrous dysplasia into osteosarcoma. *J Craniofac Surg*, 2011; 22(3):959-961.
3. Henry A. Monostotic fibrous dysplasia. *J Bone Joint Surg Br*. 1969; 51(2):300-306.
4. Sherman NH, Rao VM, Brennan RE, Edeiken J: Fibrous dysplasia of the facial bones and mandible. *Skeletal Radiol* 1982, 8(2):141-143.
5. Diah E, Morris DE, Lo LJ, Chen YR. Cyst degeneration in cranio-facial fibrous dysplasia: clinical presentation and management. *Journal of neurosurgery* 2007; 107(3):504-508.
6. Valentini V, Cassoni A, Marianetti TM, Terenzi V, Fadda MT, Iannetti G. Craniomaxillofacial fibrous dysplasia: conservative treatment or radical surgery? A retrospective study on 68 patients. *Plastic and reconstructive surgery* 2009, 123(2):653-660.
7. Michael CB, Lee AG, Patrinely JR, Stal S, Blacklock JB. Visual loss associated with fibrous dysplasia of the anterior skull base. Case report and review of the literature. *Journal of neurosurgery* 2000; 92(2):350-354.
8. Lee JS, FitzGibbon E, Butman JA, Dufresne CR, Kushner H, Wientroub S, Robey PG, Collins MT. Normal vision despite narrowing of the optic canal in fibrous dysplasia. *N Engl J Med* 2002, 347(21):1670-1676.
9. Liakos GM, Walker CB, Carruth JA. Ocular complications in craniofacial fibrous dysplasia. *Br J Ophthalmol* 1979, 63(9):611-616.
10. Cutler CM, Lee JS, Butman JA, FitzGibbon EJ, Kelly MH, Brillante BA, Feuillan P, Robey PG, DuFresne CR, Collins MT. Long-term outcome of optic nerve encasement and optic nerve decompression in patients with fibrous dysplasia: risk factors for blindness and safety of observation. *Neurosurgery* 2006, 59(5):1011-1017.
11. Papay FA, Morales L Jr., Flaharty P, Smith SJ, Anderson R, JM WA, Hood RS, Hardy S. Optic nerve decompression in cranial base fibrous dysplasia. *J Craniofac Surg* 1995; 6(1):5-10.