

Review

Narrow Band Imaging – From Technological Progress to Superior Urothelial Cancer Diagnostic

M. Jecu^{1,2}, P. Geavlete^{1,2}, I.A. Checheriță^{1,3}, C. Ene², B. Geavlete^{1,2}

¹Clinical Department No. 3, “Carol Davila” University of Medicine and Pharmacy Bucharest, Romania

²Department of Urology, “Saint John” Emergency Clinical Hospital, Bucharest, Romania

³Department of Nephrology and Dialysis, “Saint John” Emergency Clinical Hospital, Bucharest, Romania

REZUMAT

Narrow band imaging - de la progresul tehnologic la un diagnostic ameliorat în cancerul urotelial

Introducere: Cancerul vezical non-invaziv muscular (NMIBC) continuă să reprezinte o importantă problemă de sănătate în urologia modernă, fiind marcat de un diagnostic endoscopic de slabă acuratețe și, în același timp, caracterizat de rate ridicate de recurență la cistoscopia standard, în lumină albă (WLC). Dezvoltare tehnologică: Pornind de la astronomie către gastroenterologie, tehnologia narrow band imaging (NBI) s-a dezvoltat ca o metodă de diagnostic optic viabilă. Principiul vizualizării în bande de undă îngustă a găsit aplicabilitate atât la telescoape cât și în detecția cancerului gastrointestinal. Utilizarea în urologie: În practica urologică, cistoscopia în modul NBI s-a dovedit a oferi o vizualizare superioară a arhitecturii vasculare a leziunilor neoplazice, subliniind contrastul cu uroteliul normal. Pe de altă parte, tumorile papilare plate sau de mici dimensiuni, omise la cistoscopia standard au fost descoperite și rezecate numai datorită tehnologiei NBI.

Rezultate clinice: Numeroase studii clinice au confirmat rate de detecție superioară folosind metoda NBI comparativ cu cistoscopia în lumină albă. O proporție semnificativă de leziuni adiționale pTa și CIS au fost omise de metoda standard și evidențiate exclusiv de NBI. Premizele pentru impactul favorabil în tratamentul NMIBC și recurențele tumorale scăzute au fost deja dovedite.

Concluzii: Cistoscopia în NBI a crescut detecția cancerului vezical și a generat o rezecție mai extinsă a tumorilor vezicale. Viitoare studii sunt necesare pentru a dovedi, pe termen lung, viabilitatea metodei.

Cuvinte cheie: cancer vezical non-invaziv, cistoscopie în lumină albă, narrow band imaging

ABSTRACT

Introduction: Non-muscle invasive bladder cancer (NMIBC) still represents an important health care problem in modern urology, as it is marked by the low accuracy endoscopic diagnosis and high recurrence rates characterizing the standard white light cystoscopy (WLC) assessment.

Corresponding author: Bogdan Geavlete, MD, PhD
“Saint John” Emergency Clinical Hospital, Department of Urology, Vitan Barzesti Street 13
District 4, 042122, Bucharest, Romania
e-mail: bogdan_geavlete@yahoo.com

Technological development: From astronomy to gastroenterology, narrow band imaging (NBI) was developed as a reliable optical enhancement method. The principle of narrowed bandwidths vision found applicability in both telescopes and gastrointestinal carcinoma detection.

Urological use: In urological practice, NBI endoscopy was proved to provide a superior visualization of the vascular architecture of malignant lesions, thus underlining the contrast with the normal urothelium. Otherwise missed (during WLC) flat or small papillary tumors were reported as solely discovered and resected in NBI mode.

Clinical outcomes: Various studies confirmed the significantly improved tumor detection rates of NBI when compared to standard cystoscopy. A substantial proportion of additional pTa and CIS lesions were left behind by WLC and only found in NBI. The premises for a favorable impact over the NMIBC treatment outcomes and eventually reduced recurrence rates were generally outlined so far.

Conclusions: NBI vision markedly ameliorates the bladder cancer diagnostic and generates the conditions for a more comprehensive resection to be accomplished. Future research will be required to establish the long term viability of the method.

Key words: non-muscle invasive bladder cancer, white light cystoscopy, narrow band imaging

INTRODUCTION

Bladder cancer represents the most common malignancy of the urinary tract and the 7th most frequent cancer in men and 17th in women. The prevalence of this malignancy varies between regions and countries. In Europe for example, the highest age-standardized incidence rate has been reported in Spain and the lowest in Finland (1). In the United States, the incidence and mortality due to bladder cancer is also high (more than 60,000 new cases and up to 13,000 deaths annually) (2). Therefore, in the last decades, it has been noticed an increased prevalence of bladder cancer, probably caused by tobacco abuse, industrial carcinogens risk factors and overall aging process of the population (3).

75-85% of all newly diagnosed bladder tumors is represented by non-muscle-invasive bladder cancer (NMIBC), a multifocal disease, that includes stages pTa, pT1 and carcinoma in situ (CIS) (4). Furthermore, this pathology has a high recurrence rate within the first 5 years after the initial diagnosis (5), despite the recent technological advances (6).

Because standard white light cystoscopy (WLC) cannot properly visualize small papillary and CIS lesions, often a significant amount of residual tumors may be overlooked by the conventional transurethral resection (TURBT) (7). Consequently, an important number of methods have been developed over the past several years in an attempt to minimize recurrences and improve the NMIBC oncologic outcome (8). Among these investigation alternatives,

narrow band imaging (NBI) cystoscopy has become increasingly popular among urologists worldwide as it gained a growing acknowledgement as part of the consecrated NMIBC diagnostic armamentarium (9).

NBI technological development - from astronomy to medical use

Nowadays, a new method, usually utilized in astronomy, gained more interest in detecting even small tumor lesions – narrow banding. Abramo et al. showed that narrow band filters could detect with more accuracy quasars in sufficiently high number densities. In addition, this technique has the capacity to turn them into suitable tracers of large scale structure (10).

Another example proving the method efficiency was established by Anderson et al. study, in November 1999 (11). Narrow band images of Titan (taken with the Mount Wilson 2.54 m telescope using the NASA/GSFC-built Acousto-Optic Imaging Spectrometer) were used to explore the haze vertical structure in the planet's lower atmosphere (11). These pictures were recorded at 5 wavelengths surrounding the 0.94 μm methane window and proved sensitive to a wide range of altitudes in Titan's lower atmosphere (11).

While turning to potential medical uses, during live observations, it was noticed that the spectral composition of the reflected light is influenced by tissue structure and blood flow (12-14). The penetration depth of the incident photons depends on their wavelengths: superficial for the blue band, in

depth for the red band and intermediate for the green band (the range in penetration distance varies between 0.15 and 0.30 mm).

From another perspective, hemoglobin represents the major factor for the absorption of visible light with a main peak in the blue part (415 nm) of the spectrum, explaining the red color of vessels (15). On the other hand, in NBI mode, vascular structures present a different color appearance (dark brown for capillary vessels and green for veins) comparing to normal mucosa (pink or white background) (16). Subjectively speaking, NBI technology has been determined to emphasize with increased accuracy the detailed vascular architecture of lesions, creating a three-dimensional image that contributes to correctly outline tumor limits (17).

A prototype narrow band imaging (NBI) system was developed in 1999 and its' efficacy for endoscopic application in the gastrointestinal tract was initially reported in 2001 by Sano et al. (18), but, using this method, Nakayoshi et al. were the first to report the blood vessel patterns of gastric cancer – “fine network pattern” for well differentiated adenocarcinoma and “corkscrew pattern” for poorly differentiated (19). Furthermore, NBI was also successfully applied to diagnose and investigate other gastroenterological diseases (20) – adenoma detection (by colonoscopy) (21) or Barrett’s esophagus (by endoscopy) (22).

Urological practice – motive and opportunity

In urological practice, NBI proved to be a cost loss and morbidity-free procedure in accurate detecting urothelial tumors (23). Additionally, no particular learning curve in determining the presence of bladder tumors was noticed (24).

The NBI visualization mode enhances the specific tissue contrast between malignant lesions and the normal urothelium but does not require exogenous contrast agents. The technique is based on a source that filters white light into 2 wavelengths (415 and 540 nm) (Fig. 1) which are particularly well absorbed by hemoglobin, thus substantially improving the contrast between capillaries and mucosa (Fig. 2). The ameliorated contrast helps differentiating the more vascularized malignant areas from the normal urothelium. When using NBI method, surgeon’s ability is highly important to correctly interpret visual changes of vasculature structure surrounding and inside the suspicious area (8).

The main advantages of NBI are represented by no special contraindications, the requirement of no instillation or disposable items, and the use for an unlimited number of times and no maximum duration for each procedure with minimal costs (related to the initial investment in the actual device – a software modification to the endoscope’s optical structures) (25).

Clinical outcomes – from promising to evidence based oncologic progress

In a study by Bryan et al., NBI flexible cystoscopy was performed in cases of known recurrences of bladder urothelial cancer after the initial flexible WLC has been already completed. NBI detected 15 additional lesions in 35% of the involved patients, thus confirming the significantly improved sensitivity over the conventional endoscopic evaluation (26).

Cauberg et al. conducted a prospective and comparison study including 103 consecutive procedures on 95 patients scheduled for re-TURBT or bladder biopsies (19). WLC and NBI cystoscopies were performed by different surgeons who indepen-

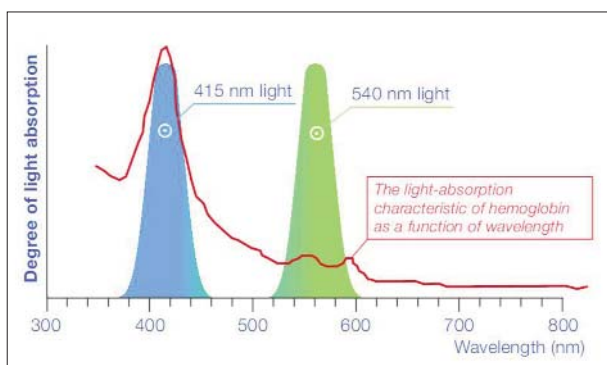


Figure 1*. Degree of light absorption in NBI
*Copyright – Courtesy of Olympus Europa SE & CO KG

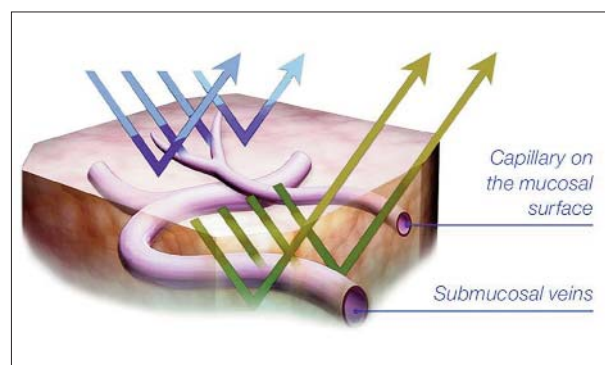


Figure 2*. Capillaries and veins in NBI mode
*Copyright – Courtesy of Olympus Europa SE & CO KG

dently indicated all found tumors and suspect areas on a bladder diagram (19,27). In 35.9% of the cases, a total proportion of 17.3% additional tumors were detected by NBI alone, whereas only 1.8% of the existing lesions were singularly discovered during WLC in 2.9% (19,27). Ultimately, a significantly increased tumor' detection rate was established for NBI when compared to WLC (94.7% versus 79.2%), at the cost of a higher rate of false-positive results (31.6% versus 24.5%) (19,27).

From another perspective, Herr et al. studied a cohort of 126 patients with recurrent low grade papillary bladder tumors which were followed every 6 months for a period of 3 years by classical WLC, and afterwards over the next 3 consecutive years by NBI cystoscopy. A total of 94% of the assessed cases displayed tumor recurrences during WLC by comparison to 62% while applying NBI cystoscopy. The mean number of white light discovered recurrent tumors was 5.2 and 2.8 subsequent to the NBI visualization, while the respective median recurrence-free survival times were 13 versus 29 months. Based on these data, the authors underlined the fact that the NBI evaluation protocol was associated with fewer patients having tumor recurrences, a reduced number of recurrent tumors as well as a longer recurrence-free survival time (28).

Further more on the path of clinical research, Naselli et al. analyzed the impact of NBI diagnostic modality concerning the 1 year' NMIBC specific recurrence risk – 32.9% rate in the NBI and 51.4% in the WL group, respectively (23). The incidence of false-positive findings was 28% for NBI cystoscopy and 21% for WLC, respectively (23). The findings of the trial underlined the idea that the NBI assisted TURBT manages to reduce the 1 year' risk of NMIBC recurrence by at least 10% (23).

High-grade bladder cancer constitutes an entity characterized by an increased rate of recurrence and progression. For this purpose, Naselli et al. conducted another study to establish whether NBI may be useful in discovering high-grade malignant lesions missed in white light at the time of a second TURBT in previously confirmed high-grade NMIBC cases (25). One month after the initial resection, NBI guided cold-cup biopsies were taken from areas suspicious for urothelial cancer in 85.1% of patients, revealing 13% rate of high-grade lesions (overall, 34% of the cases were found to have residual/recurrent tumors subsequent to re-TUR and NBI biopsies) (25). Concluding, NBI guided biopsy is

mandatory in subjects with newly diagnosed high-grade NMIBC, because it can detect otherwise missed lesions (25).

While referring to a relatively different area of interest, upper urinary tract transitional-cell carcinoma (UUT-TCC) diagnosis always represented a challenge for modern endourology. Traxer et al. published the first paper regarding the use of NBI assisted digital flexible ureteroscopy as part of the diagnostic protocol in this pathology.

Interestingly enough, NBI technology allowed the discovery and more accurate visualization of UUT-TCC lesions as well as identifying extended tumoral limits. In 38.4% of the included patients with newly diagnosed UUT-TCC, the NBI assessment was able to provide additional diagnostic information. NBI exclusively emphasized 14.2% of additional tumors and established the presence of extended limits for another 8.5% of the existing lesions. Consequently, the tumor detection rate was found to improve by 22.7% when using the NBI mode. In light of the respective findings, the authors underlined NBI as a remarkably valuable diagnostic technology for UUT-TCC pathology, showing considerable improvement of tumor visual accuracy and detection rate. Additionally, a significantly superior delineation of the precise tumor limits became possible, thus enabling the urologist to achieve a complete laser vaporization treatment (17).

CONCLUSIONS

From astrology to gastroenterology, the basic principle of narrow bandwidths' visualization took advantage from a certified acknowledgement towards technological progress. Further along the line of medical care, it could be concluded that NBI endoscopy constitutes a promising diagnostic tool in the modern endourological armamentarium.

In light of the above evidence based benefits of NBI vision, this type of cystoscopic evaluation was characterized by subjectively ameliorated tumoral visual differentiation and clinically certified superior detection rates. Furthermore, this technique improves oncologic prognosis and NBI guided TURBT constitutes an efficient treatment option comparing to the standard white light resection.

Most certainly, extensive follow-up periods and well established trials remain absolutely essential while aiming to determine the rightful place of the

NBI modality as part of the urothelial cancer diagnostic and therapeutic management.

REFERENCES

1. Ferlay J, Bray F, Forman D, et al. GLOBOCAN 2008 v1.2, Cancer Incidence and Mortality Worldwide: IARC CancerBase No. 10 2010, International Agency for Research on Cancer: Lyon, France; <http://globocan.iarc.fr/>; accessed July 2014.
2. Cancer Facts and Figures 2007. Atlanta: American Cancer Society 2007; <http://www.cancer.org/acs/groups/content/@nho/documents/document/caff2007pwsecuredpdf.pdf>; accessed July 2014.
3. Ries LA, Eisner MP, Kosary CL, Hankey BF, Miller BA, Clegg L et al. SEER Cancer Statistics Review, 1975-2000. Bethesda: National Cancer Institute, 2003; http://seer.cancer.gov/archive/csr/1975_2000; accessed July 2014.
4. Grasso M. Bladder cancer: a major public health issue. *Eur Urol Suppl.* 2008; 7:510-5.
5. Sylvester RJ, van der MEIJDEN AP, Lamm DL. Intravesical bacillus Calmette-Guerin reduces the risk of progression in patients with superficial bladder cancer: a meta-analysis of the published results of randomized clinical trials. *J Urol.* 2002; 168(5):1964-70.
6. Geavlete B, Stynesu F, Moldoveanu C, Jecu M, Adou L, Bulai C, Ene C, Geavlete P. NBI cystoscopy and bipolar electrosurgery in NMIBC management - An overview of daily practice. *J Med Life.* 2013; 6(2):140-5.
7. Jocham D, Stepp H, Waidelich R. Photodynamic diagnosis in urology: state-of-the-art. *Eur Urol.* 2008; 53:1138-50.
8. Liu JJ, Droller MJ, Liao JC. New optical imaging technologies for bladder cancer: considerations and perspectives. *J Urol.* 2012; 188(2):361-8.
9. Tatsugami K, Kuroiwa K, Kamoto T, Nishiyama H, Watanabe J, Ishikawa S, Shinohara N, Sazawa A, Fukushima S, Naito S. Evaluation of narrow-band imaging as a complementary method for the detection of bladder cancer. *J Endourol.* 2010; 24(11):1807-11.
10. Abramo LR, Strauss MA, Lima M, Hernandez-Monteagudo C, Lazkoz R, Moles M, de Oliveira CM, Sendra I, Sodri L, Storchi-Bergmann T. Measuring large-scale structure with quasars in narrow-band filter surveys. *Monthly Notices of the Royal Astronomical Society.* 2012; 423:3251-67.
11. Anderson CM, Chanover NJ, McKay CP, Rannou P, Glenar DA, Hillman JJ. Titan's haze structure in 1999 from spatially-resolved narrowband imaging surrounding the 0.94 μm methane window. *Geophys Res Lett.* 2004; 31, L17S06, doi:10.1029/2004GL019857.
12. Gono K, Obi T, Yamaguchi M, Ohyama N, Machida H, Sano Y, Yoshida S, Hamamoto Y, Endo T. Appearance of enhanced tissue features in narrow-band endoscopic imaging. *J Biomed Opt.* 2004; 9(3):568-77.
13. Gono K, Yamazaky K, Doguchi N. Endoscopic observation of tissue by narrowband illumination. *Optical Rev.* 2003; 10:1-5.
14. Gono K, Yamaguchi M, Ohyama N. Improvement of image quality of the electroendoscope by narrowing spectral shapes of observation light. *Proc Int Congress Imaging Sci.* 2002; 5:399-400.
15. Ueda T, Nakagawa M, Okamura M, Tanoue H, Yoshida H, Yoshimura N. New cystoscopic diagnosis for interstitial cystitis /painful bladder syndrome using narrow-band imaging system. *Int J Urol.* 2008; 15(12):1039-43.
16. Cauberg EC, de Bruin DM, Faber DJ, van Leeuwen TG, de la Rosette JJ, de Reijke TM. A new generation of optical diagnostics for bladder cancer: technology, diagnostic accuracy, and future applications. *Eur Urol.* 2009; 56(2):287-96.
17. Traxer O, Geavlete B, de Medina SG, Sibony M, Al-Qahtani SM. Narrow-band imaging digital flexible ureteroscopy in detection of upper urinary tract transitional-cell carcinoma: initial experience. *J Endourol.* 2011; 25(1):19-23.
18. Sano Y, Kobayashi M, Hamamoto Y et al. New diagnostic method based on color imaging using narrow band imaging (NBI) system for gastrointestinal tract. *Gastrointest. Endosc.* 2001; 53:AB125.
19. Nakayoshi T, Tajiri H, Matsuda K, Kaise M, Ikegami M, Sasaki H. Magnifying endoscopy combined with narrow band imaging system for early gastric cancer: correlation of vascular pattern with histopathology (including video). *Endoscopy.* 2004; 36(12):1080-4.
20. Lambert R, Kuznetsov K, Rey J. Narrow-band imaging in digestive endoscopy. *Scientific World Journal.* 2007; 30(7):449-65.
21. Inoue T, Murano M, Murano N, Kuramoto T, Kawakami K, Abe Y, Morita E, Toshina K, Hoshiro H, Egashira Y, Umegaki E, Higuchi K. Comparative study of conventional colonoscopy and pan-colonic narrow-band imaging system in the detection of neoplastic colonic polyps: a randomized, controlled trial. *J Gastroenterol.* 2008; 43:45-50.
22. Sharma P, Bansal A, Mathur S, Wani S, Cherian R, McGregor D, Higbee A, Hall S, Weston A. The utility of a novel narrow band imaging endoscopy system in patients with Barrett's esophagus. *Gastrointest Endosc.* 2006; 64:167-75.
23. Naselli A, Introini C, Timossi L, Spina B, Fontana V, Pezzi R, Germinale F, Bertolotto F, Puppo P. A randomized prospective trial to assess the impact of transurethral resection in narrow band imaging modality on non-muscle-invasive bladder cancer recurrence. *Eur Urol.* 2012; 61(5):908-13.
24. Herr H, Donat M, Dalbagni G, Taylor J. Narrow-band imaging cystoscopy to evaluate bladder tumours--individual surgeon variability. *BJU Int.* 2010; 106(1):53-5.
25. Naselli A, Introini C, Bertolotto F, Spina B, Puppo P. Narrow band imaging for detecting residual/recurrent cancerous tissue during second transurethral resection of newly diagnosed non-muscle-invasive high-grade bladder cancer. *BJU Int.* 2010; 105(2):208-11.
26. Bryan RT, Shah ZH, Collins SI, Wallace DM. Narrow-band imaging flexible cystoscopy: a new user's experience. *J Endourol.* 2010; 24(8):1339-43.
27. Cauberg EC, Kloen S, Visser M, de la Rosette JJ, Babjuk M, Soukup V, Pesl M, Duskova J, de Reijke TM. Narrow band imaging cystoscopy improves the detection of non-muscle-invasive bladder cancer. *Urology.* 2010; 76(3):658-63.
28. Reduced bladder tumour recurrence rate associated with narrow-band imaging surveillance cystoscopy. *BJU Int.* 2011; 107(3):396-8.